THE BIOMECHANICS OF MENISCAL TEARS AND REPAIRS IN CADAVERIC DOG STIFLES

By

KELLEY MAUREEN THIEMAN

A THESIS PRESENTED TO THE GRADUATE SCHOOL
OF THE UNIVERSITY OF FLORIDA IN PARTIAL FULFILLMENT
OF THE REQUIREMENTS FOR THE DEGREE OF
MASTER OF SCIENCE

UNIVERSITY OF FLORIDA

2009

To everyone who helped me learn about and love the meniscus

ACKNOWLEDGMENTS

I thank my family for their support during my many years of education. I thank my advisor, mentor, co-investigator, and friend, Dr. Antonio Pozzi, for his patience and guidance. I would like to thank Drs. Daniel Lewis and Carrie Ling for their help and guidance during this project. Special thanks go to Dr. Jimi Cook and David Shepard for their valuable contributions. I also thank Tim Vojt for producing the beautiful figures in this manuscript.

TABLE OF CONTENTS

LIST OF TABLES

LIST OF FIGURES

Abstract of Thesis Presented to the Graduate School
of the University of Florida in Partial Fulfillment of the
Requirements for the Master of Science

THE BIOMECHANICS OF MENISCAL TEARS AND REPAIRS IN CADAVERIC DOG STIFLES

By

Kelley Maureen Thieman

December 2009

Chair: Antonio Pozzi
Major: Veterinary Medical Science

Medial meniscal tears are a common sequela to cranial cruciate ligament rupture in the dog. Medial meniscal tears lead to pain, inflammation and eventually degenerative joint disease in the stifle. Historically, torn menisci have been removed from the joint. Studies show that meniscectomy will lead to degenerative joint disease. For this reason, portions of the meniscus are preserved if possible using either partial meniscectomy or, more often in humans, meniscal repair. The objectives of this study were to review the literature regarding meniscal tears in dogs, and to investigate the effects of meniscal tears, meniscal repairs and partial meniscectomy on femorotibial contact mechanics in dog stifles during weight-bearing.

Medial meniscal lesions (radial, vertical longitudinal, non-reducible bucket handle, flap, complex tears) were simulated in cadaveric dog stifles. A contact map was recorded from each tear type and peak contact pressure from each tear type was compared. A significant difference in peak contact pressure was detected between control and non-reducible bucket handle, flap, and complex tears. Peak contact pressure increased by >45% in non-reducible bucket handle, flap, and complex meniscal tears when compared with control.

In a different set of cadaveric dog stifles, simulated bucket handle medial meniscal tears were created in cadaveric dog stifles. Tears were treated with one of three suture repair techniques or partial meniscectomy. Contact area (CA), mean contact pressure (MCP), and peak contact pressure (PCP) measurements were recorded with the pressure sensing system. All meniscal repair techniques reestablished normal contact mechanics. When comparing meniscal repair and partial meniscectomy, stifles with partial meniscectomy had approximately 35% lower CA, 57% higher MCP, and 55% higher PCP than stifles undergoing repair.

CHAPTER 1
MENISCAL INJURIES IN DOGS: FROM BASIC SCIENCE TO TREATMENT

Introduction

In 1897, the knee menisci were described as "functionless remains of leg muscle origins".[1] Since that time, our understanding of the structure and function of the menisci has evolved greatly. Until the 1980s, meniscectomy was performed routinely and thought to be a benign procedure involving the removal of a diseased, functionless, redundant structure.[1] In the 1930s, an increasing number of anatomists suggested that menisci were an important, functional component of the knee joint.[2-4] Based on experiments involving partial and total meniscectomy in dogs, King concluded that the menisci served to protect the articular cartilage from degeneration.[4] In a paper read in 1947 at the Annual Session of the American Medical Association, Lipscomb argued against routine removal of the entire meniscus, as he had observed no clinical difference between patients which had undergone partial resection compared to those patients that had undergone total meniscectomy.[5] Lipscomb's statement was supported by a study by Fairbank performed in dogs which found that meniscectomy interferes with the mechanics of the joint.[6] Fairbank was the first to suggest a direct load-bearing role of the menisci and showed an increased incidence of degenerative changes of the articular surface of the stifle of dogs after meniscectomy due to the loss of load-bearing function of the menisci.[6] In spite of these studies, total meniscectomy was commonly performed in human patients until the 1980s.

The results of several experimental and clinical studies on menisci support conservation of meniscal tissue when possible.[7-9] Although this new realization of the critical role of the menisci in normal knee function has led to increased efforts to

preserve injured menisci in human patients whenever possible, meniscal tears in dogs are still commonly treated with meniscectomy.[10, 11] The following review will discuss basic science and the advances in meniscal treatment in dogs.

Functional Anatomy

The stifle is a diarthrodial joint with articulating surfaces of highly dissimilar geometry in which the menisci play several important roles.[12, 13] The congruity between femur and tibia is improved by the concave articular surface created by the menisci.[14, 15] The menisci are C-shaped disks of fibrocartilage located between the condyles of the femur and the tibia, one positioned between the medial condyles and the other between the lateral condyles (figure 1-1).[14, 16] The peripheral border of each meniscus is thick while the axial border tapers to a thin free edge yielding a triangular cross sectional shape. The proximal surfaces of the menisci are concave and articulate with the femoral condyles while the distal surfaces of the menisci are flat and rest on the tibial plateau. The menisci are held in place by ligaments and soft tissue attachments.[14] The attachments of the meniscus to the tibia are necessary for normal mechanical function and are part of the functional unit of the meniscus.[17, 18]

The menisci are poorly vascularized structures. Blood vessels penetrate the peripheral 25% of the width of the meniscus.[19] Although the peripheral portion of the meniscus is vascularized, most of the meniscus is avascular and must rely to a large degree on synovial fluid for nutrition. Small pores in the meniscus communicate with a network of canals between the collagen bundles. When the stifle is loaded and unloaded, synovial fluid is pumped in and out of the canals to supply nutrition to the fibrochondrocytes located in the avascular parenchyma of the menisci.[20]

The innervation of the meniscus has been extensively studied in humans and animals.[21-24] Myelinated and unmyelinated fibers penetrate the peripheral portion of the menisci with a wider distribution of nerve fibers found in the cranial and caudal horns. Studies in human specimens have shown that there are a high number of mechanoreceptors within the medial meniscus.[23] These findings suggest that the medial meniscus may have proprioceptive functions in humans. While fewer in number than other nerve fibers, nociceptive fibers have a similar distribution to the meniscal tissue. Nociceptive fibers are present in the periphery of the menisci with wider distribution in the cranial and caudal horns.[24]

Meniscal Ultrastructure

The menisci are fibrocartilaginous structures consisting of collagen, proteoglycans, cells and water. Meniscal tissue contains different molecular species of collagen, but type I is the predominant type and accounts for more than 90% of the total collagen present. Collagen fibers have a definite pattern of orientation within the meniscus that can be related to the mechanical function of the meniscus.[13] The surface layer of the meniscus is composed of randomly dispersed collagen fibers.[13, 25] Deeper, in the substance of the meniscal parenchyma, the majority of collagen fibers are oriented circumferentially following the curve of each crescent-shaped meniscus, and run continuously from the cranial tibial attachment to the caudal tibial attachment (figure 1-2). A minority of the collagen fibers is oriented radially; these fibers run from the periphery to the axial portion of the meniscus. The radially oriented fibers act as “tie fibers” and ensure that the surface of the meniscus is mechanically linked to the bulk of the meniscus.[13, 25] The circumferential orientation of the collagen bundles allows the meniscus to withstand compression forces transmitted between the femur and tibia. At

the concave femoro-meniscal surface, the force originating from weight-bearing has a vertical and a radial component Kambic (Figure 1-3). To balance the radial component of the femoro-meniscal force, internal forces must be developed along the circumferentially arranged collagen fiber bundles. These forces are aligned tangent to the collagen fibers and create hoop strains.[26]

Proteoglycans are critically important in the maintenance of hydration, firmness and elasticity of the menisci. The overall proteoglycan content of the meniscus is relatively small, but this can vary with the age of the animal. Proteoglycans are composed of a large protein core to which many chondroitin sulfate, keratan sulfate and other glycosaminoglycan chains are attached. The chondroitin sulfate and keratin sulfate chains of the proteoglycan contribute to important functions of these molecules. The proteoglycans are composed of disaccharide units that become dissociated and charged in the interstitum of the tissue. The resultant ionic charge results in increased interstitial osmotic pressure. These characteristics are responsible for the compressive stiffness, tissue hydration and swelling, low permeability and shear stiffness of the menisci.

Meniscal Function and Biomechanics

The role of the menisci as load bearing elements has been studied in depth in human and animal models.[12, 27, 28] Several studies have shown that meniscectomy causes an immediate, acute increase in stifle peak contact pressure and that these changes in stress distribution cause remodeling of bone and soft tissue.[12, 29-31] Ahmed and Burke reported that removal of the medial meniscus caused a reduction in the joint contact area by 50-70% and a marked increase in peak pressure in the human knee.[31] Krause showed that menisci transmit 65% of the weight-bearing across the stifles of

dogs and that a two-fold increase in compressive deformation of cartilage and subchondral bone occurred after meniscectomy.[32] Shrive reported that radial transection of the porcine and human meniscus was equivalent to meniscectomy in terms of load-bearing, suggesting the loss of hoop tension was responsible for high and non-uniform pressure distribution.[33] More recent cadaveric studies using pressure sensors to measure contact stresses have confirmed the load bearing role of the meniscus in dogs. A mid-body transection of the meniscus or a radial cut of the caudal menisco-tibial ligament caused an increase in peak stresses and a decrease in contact area similar to a meniscectomy.[29, 34] These findings confirm that the menisci can distribute the load from the femur to the tibia only if the functional unit of meniscus and soft tissue attachments is intact. By distributing loads over a larger contact area, the meniscus decreases the stress on the cartilage, and protects the chondrocytes and extracellular matrix from mechanical damage.[27, 35]

Models show that the menisci absorb energy by undergoing elongation as a load is being applied to the knee. As the joint compresses, the wedge shaped meniscus extrudes peripherally and its circumferentially oriented collagen fibers elongate.[6, 25, 26] Complete extrusion of the meniscus is prevented by the cranial and caudal attachments of the circumferential collagen fiber bundles to the tibia and hoop stresses are generated.

The load transmission and shock absorption functions of the menisci are vital for normal metabolism of the articular cartilage. If the protective function of the meniscus is lost, the increased and repetitive stress caused by axial loading of the joint will cause damage to the cartilage.[36, 37] It has been proposed that compression of the cartilage at

physiological strains serves as a signal to modulate chondrocyte responses, while prolonged compression at higher strains may be responsible for tissue and cell damage.[38] Radin et al reported that failure of a damaged or resected meniscus to attenuate peak dynamic force may predispose to subchondral bone stiffening and consequently osteoarthritis.[39] In a recent study McCann et al showed that mensicectomized bovine stifles will have increased contact stress and frictional coefficient. The meniscectomized stifles also led to immediate articular cartilage surface fibrillation when walking was simulated.[36] Furthermore, a number of studies suggest that surgical removal of the medial meniscus constitutes a risk factor for articular cartilage degeneration.[6, 7, 27, 33, 40-43;44]

Joint Stability. The meniscus is most often damaged in dogs and humans with cranial cruciate ligament (CrCL) deficient stifles, making evaluation of the unstable stifle critical. The CrCL is a primary stabilizer of the stifle, preventing cranial tibial translation. The menisci act as secondary stabilizers by acting as a wedge behind the femoral condyle, preventing cranial translation of the tibia.[45, 46] By filling the void between the curved femoral condyle and the flat tibial plateau, the medial meniscus improves joint congruity and ultimately increases contact area and stability.[30, 43] The role of the menisci changes in the CrCL deficient stifle because the joint lacks the primary stabilization of the CrCL. After rupture of the CrCL, cranial tibial displacement is controlled by collateral ligaments, menisci, joint capsule and muscle forces. The role of the meniscus shifts from being a “spacer” between femur and tibia, to be a “wedge” acting against femoro-tibial subluxation. Repetitive subluxation causes high

compression and shear forces onto the meniscus and ultimately result in a meniscal tear.

The stabilizing role of the meniscus in the treated CrCL-deficient stifle is controversial. In people, an intact meniscus is an important prognostic indicator in the anterior cruciate ligament deficient knee.[47] Its functional contributions include rotational and micro-stability which cannot be achieved solely by the surgical repair. In dogs, surgical stabilization may decrease the wedge effect of the meniscus,[45] but may not eliminate the risk of tearing in *in-vivo* conditions.[48-50] Despite the risk of late onset of meniscal tear, an intact meniscus may improve the micro-stability of a surgically stabilized CrCL-deficient stifle.

The meniscus also functions in proprioception and lubrication. The mechanoreceptors located in the meniscal horns would be activated during extreme flexion and extension of the stifle, providing the central nervous system with information regarding joint position.[21] Lubrication is facilitated because the meniscus acts as a space filler and prevents pooling of synovial fluid. The meniscus also functions to draw synovial fluid across the articular surfaces.

Incidence and Etiology of Meniscal Tears

Tearing of the medial meniscus is a common sequelae to CrCL rupture in dogs and is a common cause of joint pain in people and animals.[48, 50-58] The mechanism of meniscal injury can be explained with the anatomical features of the medial meniscus. The medial meniscus is firmly attached to the tibia by the medial collateral ligament, the synovium, and the meniscal ligaments. As a result, during cranial translation of the tibia, the caudal pole of the medial meniscus may become entrapped between the femoral

and the tibial condyles and may tear due to the shear stress applied to the caudal pole of the medial meniscus.

At the ultrastructural level, the organization of the collagen fibers helps define the mechanism by which the meniscus fails. In connective tissues, the hydrated proteoglycans are mechanically much weaker than the collagen fibers.[59] When these tissues are excessively stressed, the proteoglycans are damaged first. The crack, once started, will continue to propagate as long as the stress is maintained, and will propagate in the weaker surrounding material or along the interface rather than across the stronger fibers.[60] If compression of the meniscus produces an excessive circumferential tensile stress, the tissue will dissipate strain energy by crack propagation perpendicular to the tensile stress.

Meniscal tears are frequently diagnosed in dogs undergoing CrCL stabilization procedures. Rates of reported concurrent meniscal tear range from 34.9% to 58%.[48, 50-53, 61] Meniscal tears have been reported to occur even after a CrCL stabilization procedure has been performed. These “postliminary” tears have been reported to occur following tibial plateau leveling osteotomy,[48-50] tibial tuberosity advancement,[49, 52] cranial tibial wedge osteotomy,[61] lateral fabellotibial suture,[49, 51] and tensor fascia lata graft.[49] Postliminary meniscal tears likely occur because of an inability of CrCL stabilization techniques to completely resolve abnormal forces placed on the medial meniscus.[62]

Meniscal Healing and Regeneration

Controversy exists within the orthopedic literature regarding the ability of menisci or a meniscus-like tissue to regenerate after meniscectomy.[37, 63] In 1936 King published his classic experiment on meniscal healing performed in dogs. King showed that a lesion must communicate with the peripheral blood supply for the meniscal lesion to

heal.[37] After an injury within the peripheral vascular zone, a fibrin clot forms that is rich in inflammatory cells, originating from the synovium or from the meniscus itself.[19] Vessels from the perimeniscal capillary plexus proliferate through this fibrin "scaffold" accompanied by the proliferation of undifferentiated mesenchymal cells. Eventually the lesion is filled with a cellular, fibrovascular scar tissue that fuses the wound edges together and appears continuous with the adjacent normal meniscal fibrocartilage. If the meniscal section or tear is located in the avascular region of the meniscus, meniscal fibrochondrocytes are capable of proliferation or matrix synthesis but the mean degree of meniscal repair is less than half of that of subtotal and partial meniscectomy.[19]

Experiments in rabbit and dogs have demonstrated that after total meniscectomy there is regeneration of a structure that is similar in shape and texture to the excised meniscus.[63, 64] Fibroblasts from the synovium and joint capsule migrate onto the fibrin scaffold. These cells proliferate and synthesize a fibrous connective tissue. Within 7 months this tissue has the histologic appearance of fibrocartilage and grossly resembles a meniscus.[65] For this meniscus-like tissue to regenerate, however, the entire meniscus must be resected to expose the vascular synovial tissue, or in case of a sub-total meniscectomy the excision must extends into the vascularized periphery. Despite the gross resemblance this regenerated meniscus has to a normal meniscus, the functions of an intact meniscus are lost. Due to the biomechanical importance of the meniscus and the lack of functional relevance of the repaired meniscal tissue, the most conservative approach to meniscectomy is recommended.

Clinical Signs and Diagnosis of Meniscal Tears

Meniscal tears are most commonly associated with CrCL rupture in dogs. Clinical signs include crepitus, effusion, and pain on palpation of the stifle. A "meniscal click" is

detected in approximately 25% of dogs with meniscal tears.[49] Because clinical signs of meniscal injuries could be attributed to CrCL rupture, little clinical data is available regarding isolated meniscal tears in dogs. Flo has proposed that dogs with CrCL rupture and medial meniscal tears have increased severity and duration of lameness when compared to dogs with CrCL rupture alone.[58] Recently, this concept has been supported with force plate analysis.[66] In this study, serial force plate analysis was used to detect acute deterioration of limb function in CrCL-deficient dogs. Exacerbation of lameness was 52% sensitive and 72% accurate in identifying moderate to severe meniscal injury.[66] These studies indicate that a dog with a chronic CrCL rupture and acute worsening of lameness is likely to have experienced a medial meniscal tear.

Radiographic examination may help confirm the diagnosis of CrCL rupture and meniscal tear by ruling out other stifle pathology and identifying characteristic osteoarthritic and soft tissue changes. Additional information may be gleaned from less invasive methods prior to performing arthrotomy or an arthroscopy. Magnetic resonance imaging, computed tomographic arthrography or ultrasonogrophy may be used to diagnose meniscal tears. MRI has been used in animal patients, but is not always available or financially palatable. A study in dogs reports 100% sensitivity and 94% specificity in diagnosing medial meniscal injuries using MRI.[67] Another valid imaging technique is CT arthrogram.[68, 69] Advantages of this technique include the ability to perform multiplanar reconstructions to evaluate the continuity of the cranial and caudal cruciate ligaments as well as its increasing availability in university and private veterinary referral centers. Conflicting reports exist regarding the benefit of CT arthrogram. In one study, CT arthrogram was shown to be a poor method of detection

of meniscal tears with 64.3% sensitivity and 73.3% specificity.[69] In a different study, sensitivity was reported to be 90% and specificity was 100%.[70] Ultrasound has been shown to be effective as a noninvasive method for accurately diagnosing meniscal pathology.[71] Ultrasound was shown to be 90% sensitive and 92.9% specific but requires a skilled ultrasonographer.[71]

Histopathology of Meniscal Tear

Meniscal tears are the most common pathologic change encountered in the meniscus. The microscopic appearance is similar regardless of the tear type. The round edges show proliferation of cells that look round instead of spindled. Pathologic changes may include mucoid degeneration, chondrocyte proliferation, calcification, fragmentation, tearing of collagen bundles and necrosis.[72] Inflammation and granulation tissue are not present in tears occurring in the more central parts of the meniscus. When the peripheral part of the meniscus is also torn, hemorrhage and vascular proliferation may be evident.

Degenerative changes of the meniscus may be seen very early in the pathogenesis of the CrCL-deficient stifle. Adams et al were the first to describe severe gross morphological changes of the menisci following CrCL transection in dogs, including fibrillations and tears of the meniscal tissue.[73] They also reported an early reduction in the meniscal glycosaminoglycan content of the menisci, followed by return to normal glycosaminoglycan content after 3-18 months post-injury. Jackson et al suggested that subtle histologic changes are present in grossly normal menisci from dogs with naturally occurring rupture of the CrCL.[72]

Surgical Techniques

In human orthopedics in the late 1960s and early 1970s, surgeons recognized that torn menisci were a source of clinical pain and the standard treatment for any proven meniscal tear was arthrotomy and total meniscectomy. The short term results with this treatment were satisfactory. During 1970s and 1980s, numerous research groups began looking at the biomechanical consequences of meniscectomy, stimulated by the increasing evidence of adverse late clinical sequelae resulting from total meniscectomy.[7, 8, 12, 13, 26, 32, 33, 39, 74, 75]

The results of these studies triggered the adoption of more conservative treatment of meniscal tear, with the hope of improving the long-term results after treatment of meniscal pathology. Thus, the basic clinical principle of contemporary treatment of meniscal injuries is to preserve as much functional meniscal tissue as possible while addressing the clinical symptoms caused by meniscal tears.

In veterinary orthopedics, currently the standard of care is directed toward performing partial or complete meniscectomy if the meniscus is torn.[76] First, the clinician should diagnose if there is meniscal pathology, and classify the type of tear. This can be done by MRI, CT arthrogram, ultrasound, arthroscopy or open arthrotomy. If the clinician has a high suspicion of a CrCL tear in association with a meniscal tear, arthroscopy or an open arthrotomy is usually performed and stifle stabilization is performed concurrently. The following techniques for treatment of meniscal injuries are explained in detail: total meniscectomy, caudal pole hemimeniscectomy (segmental meniscectomy), partial meniscectomy meniscal release, and meniscal repair.

Total Meniscectomy

Total medial meniscectomy is defined as removal of the entire medial meniscus. After separating the medial meniscus from the peripheral synovial membrane, the caudal and cranial meniscotibial ligaments are transected and the meniscus is circumferentially excised (Figure 1-4).[77] Advantages of this procedure include removal of tears of the meniscus that are not visualized and opening an access to the vascular capsular attachments, which allows regeneration.[63] The disadvantages are an increase in contact stress, a greater degree of osteoarthritis and a loss of stifle stability[6, 7, 7, 27, 40-43]. Total meniscectomy, once the standard treatment for all types of meniscal tears, is now rarely performed. Only occasionally is a meniscus so severely and extensively damaged that removal of the entire meniscus is necessary.

Caudal Pole Hemimeniscectomy (Segmental Meniscectomy)

Most injuries of the medial meniscus involve the caudal pole, which may present with minimally displaced tears or may be folded forward under the femoral condyle.[57;78] In this position the caudal pole of the medial meniscus becomes crushed as a result of the shear force induced by the femoral condyle. The recommended treatment for many caudal pole meniscal injuries is caudal pole hemimeniscectomy, also known as segmental meniscectomy (Figure 1-5). After medial or caudo-medial arthrotomy, the peripheral rim of the caudal pole of the medial meniscus is separated from synovial membrane and the meniscus is radially transected at the level of the medial collateral ligament. Next, the caudal meniscotibial ligament is transected and the entire caudal pole is excised.[42]

Partial Meniscectomy

Partial meniscectomy will preserve some of the load distribution function of the meniscus when the menisco-tibial ligaments are preserved.[79] Axial load across the joint is counteracted by circumferential hoop tension which transmits through the circumferentially oriented collagen fibers to the cranial and caudal menisco-tibial ligaments.[33] A radial cut through the meniscus eliminates the hoop tension and disrupts the load transmission function of the meniscus.[33] A radial cut is therefore equivalent to meniscectomy in loading terms and should be avoided when performing partial meniscectomy.[33]

Preservation of an intact peripheral rim of meniscal parenchyma results in development of less severe osteoarthritis than that associated with complete meniscectomy.[80, 81] Baratz studied the effect of partial and complete meniscectomy on contact area and contact stress in human knees[43]. He found that after partial meniscectomy, contact areas decreased approximately 10%, and peak local contact stresses increased approximately 65%. After total meniscectomy, contact areas decreased approximately 75%, and peak local contact stresses increased approximately 235%. He concluded that partial meniscectomy was valuable to protect the articular cartilage.[43] A similar evaluation of partial meniscectomy has been performed on dog stifles. This study showed that a 75% meniscal width partial meniscectomy caused a nearly 90% increase in peak contact pressure and nearly 50% decrease in contact area.[79] These studies are further supported by a study showing that greater size of meniscal resection is associated with radiographic evidence of more severe osteoarthritis in people.[81]

Meniscal tears that do not extend to the peripheral rim may be treated with partial meniscectomy. A partial meniscectomy (figure 1-6) consists of removing the axial damaged section of the meniscus, while preserving the cranial and caudal meniscotibial ligaments[14, 57]. The surgeon grasps the axial section of the meniscus to be excised. With a surgical blade or arthroscopic instrumentation, the cranial and caudal axial attachments of the segment are transected. These transections allow the removal of a smooth arc of tissue. The result is a smooth axial border to the remaining meniscus. While performing a partial meniscectomy, the surgeon should preserve the peripheral, healthy meniscal parenchyma and the meniscal attachments to the tibia.

Meniscal Release

Previous studies have suggested that late meniscal injury occurs because of an inability to correct all abnormal forces present in the CrCL deficient stifle.[62] Some surgeons elect to perform a medial meniscal release to allow the meniscus to shift its position during weight bearing and avoid injury.[82] Meniscal release may be performed as either a caudal meniscal release or a mid-body meniscal release.[82] In the caudal meniscal release, the caudal meniscotibial ligament is transected. The mid-body meniscal release is performed by a radial transection of the menicus at the level of the medial collateral ligament.[83] In a cadaveric study, the caudal meniscal release resulted in the meniscus relocating more caudolaterally than the mid-body meniscal release.[84] Although menisci undergoing caudal meniscal release displaced more, both meniscal release methods were thought to be effective in ameliorating medial meniscal compression.[84] Meniscal release was proposed to prevent postliminary meniscal tears.[83] Slocum theorized that by transecting the meniscus, the meniscus would have freedom to move caudolaterally, preventing damage.[83] Unfortunately, the theory does

not hold true as postliminary tears have been reported to occur after meniscal release.[48] Meniscal release has been shown to alter the contact mechanics of the stifle by increasing contact pressures.[85] Additionally, meniscal release alone has been shown to lead to articular cartilage pathology in dogs with intact CrCL.[86]

Meniscal Repair

Meniscal repairs have been performed clinically in dogs, but not routinely.[87-89] Conflicting data have been reported on the success of meniscal repair in dogs. In previous experimental studies performed in dogs, meniscal healing has been achieved with repair of meniscal tears involving the vascular zone of the meniscus.[90-93] In a study by Newman et al, tears were surgically created in dog stifles and underwent repair. Those dogs' menisci healed without leading to femoral or tibial articular cartilage damage.[92] Although surgically created lesions have been successfully repaired immediately following creation, many dogs are not presented to the surgeon immediately after experiencing a meniscal tear. With a chronic meniscal tear, the meniscus undergoes degenerative changes within 24 weeks.[94] After this time, the meniscal changes may lead to failure of meniscal repair if performed.[94] In human patients, early repair within 3 months of sustaining the meniscal tear yielded better results (91% success) than if carried out later (58% success).[95] Interestingly, dogs with CrCL rupture and grossly normal medial menisci have been shown to have mild histologic changes within the medial meniscus.[96] These studies imply that repair of meniscal tears may protect the articular cartilage from damage but further studies to assess the efficacy of meniscal repairs to alleviate pain and to potentiate successful healing need to be performed.

There are several methods of meniscal repair that have been used in humans. Four techniques for meniscal repair are used: open meniscal repair, arthroscopic inside-out repair, arthroscopic outside-in repair, and arthroscopic all-inside repair. The application is a matter of the surgeon's preference and experience. The main advantage of meniscal repair is that the meniscus is left completely in situ and repair can restore normal contact mechanics.[97] The disadvantages include the technical difficulty and the potential for the meniscus to fail to heal.

Meniscal Replacement and Scaffolds

When meniscal repair is not feasible, synthetic, autograft, and allograft replacements of meniscus are considered to reduce the potential for progressive osteoarthritis associated with meniscectomy in human patients. The aims of a meniscal replacement are: 1) to reduce the pain experienced by some patients following meniscus resection; 2) to prevent the degenerative changes of cartilage and the changes in subchondral bone following meniscus resection; 3) to avoid or reduce the risk of osteoarthritis following meniscus resection; 4) to restore optimally the mechanical properties of the knee joint after meniscal resection. The results of meniscus transplantation have been studied in animals. There is no proof from these experiments that replacement of a meniscus can reduce the risk of arthritis. Many different materials, both natural and synthetic, have been evaluated for meniscal replacements.[98-107] Sizing difficulty, the possibility of disease transmission and the possibility of immune reactions limit the use of allograft tissue in human patients. Indications for meniscal allografts, however, include large, irreparable lesions resulting in loss of meniscal function with joint pain and instability. Meniscal allografts often attain a good to excellent result and patients report pain reduction after implantation.[108]

Conclusion

Meniscal tears are an important cause of stifle pain and dysfunction especially in dogs with cranial cruciate ligament insufficiency. Since the 1980s there has been a shift toward preservation of meniscal parenchyma when treating meniscal tears. That shift is evidenced by the fact that today partial meniscectomy is utilized more frequently than total meniscectomy. In human medicine, attempts to preserve meniscal parenchyma include meniscal repair and replacement. Utilization of these techniques in dogs is rare and outcomes associated with these techniques in clinical cases are rarely reported. Further research is warranted to determine the best treatment for meniscal tears in dogs.

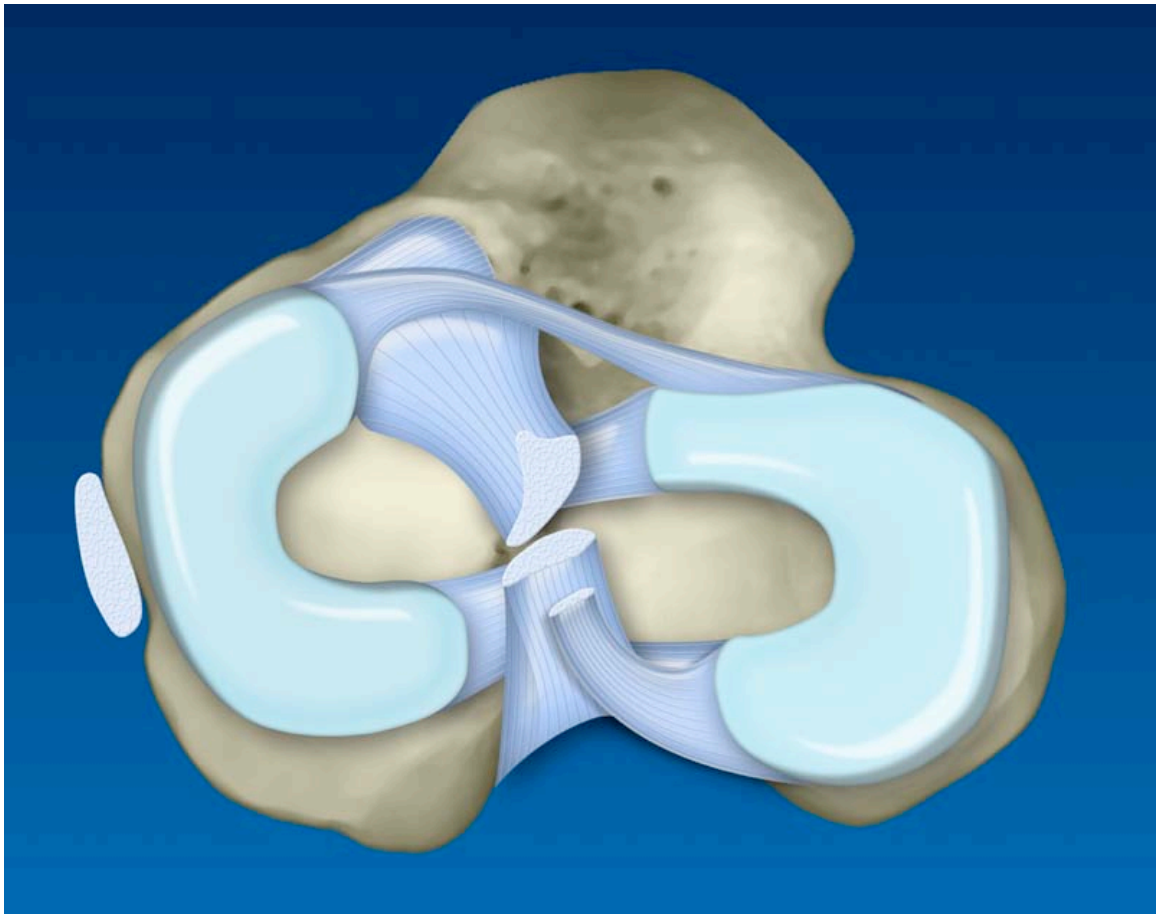

Figure 1-1. A right tibial plateau with intact menisci which are C-shaped disks of fibrocartilage located upon the medial and lateral tibial condyles.

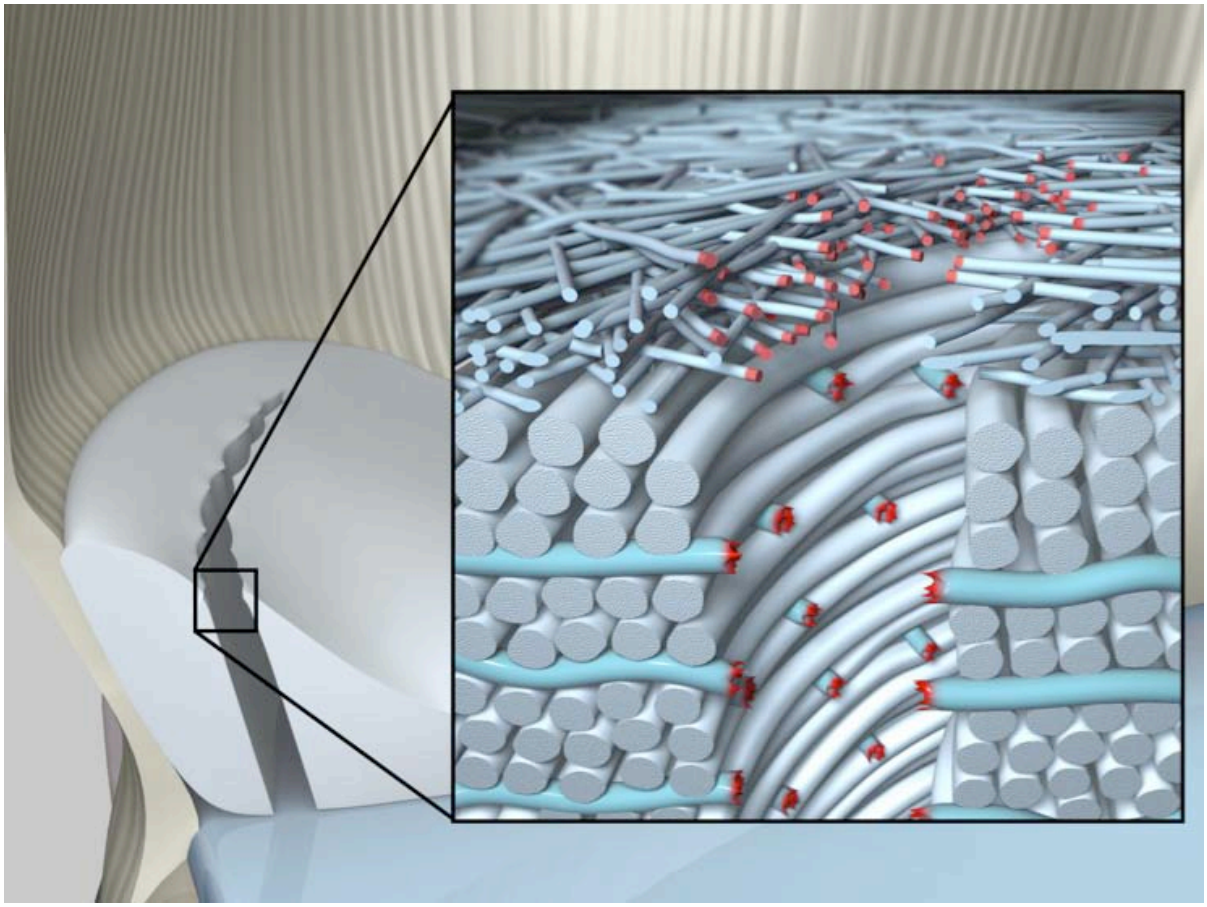

Figure 1-2. A torn meniscus viewed from within the joint. Expanded view is of the microstructure of the meniscus demonstrating the random collagen distribution superficially and the deeper circumferentially oriented collagen bundles with radial collagen “tie fibers”.

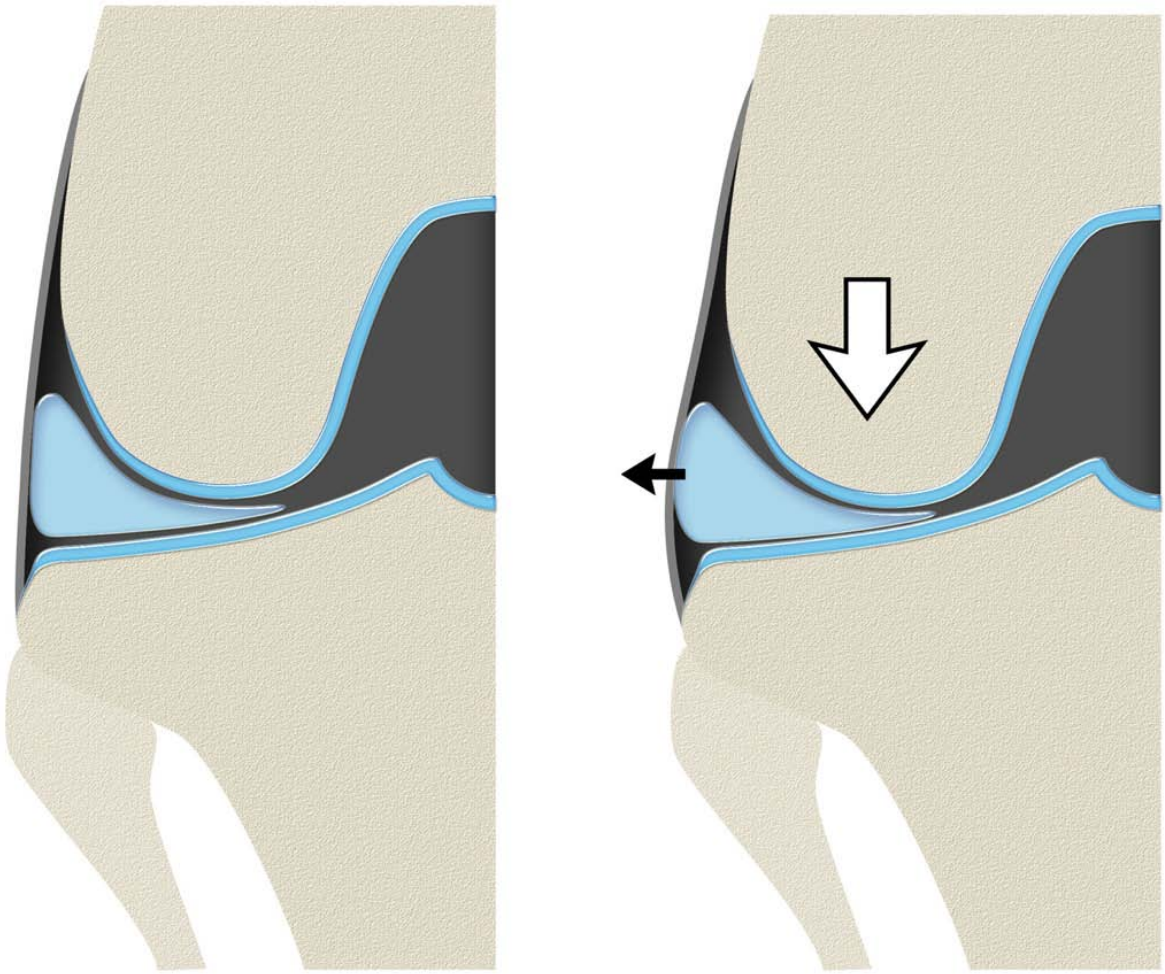

Figure 1-3. Depiction of the forces present on an axially loaded meniscus.

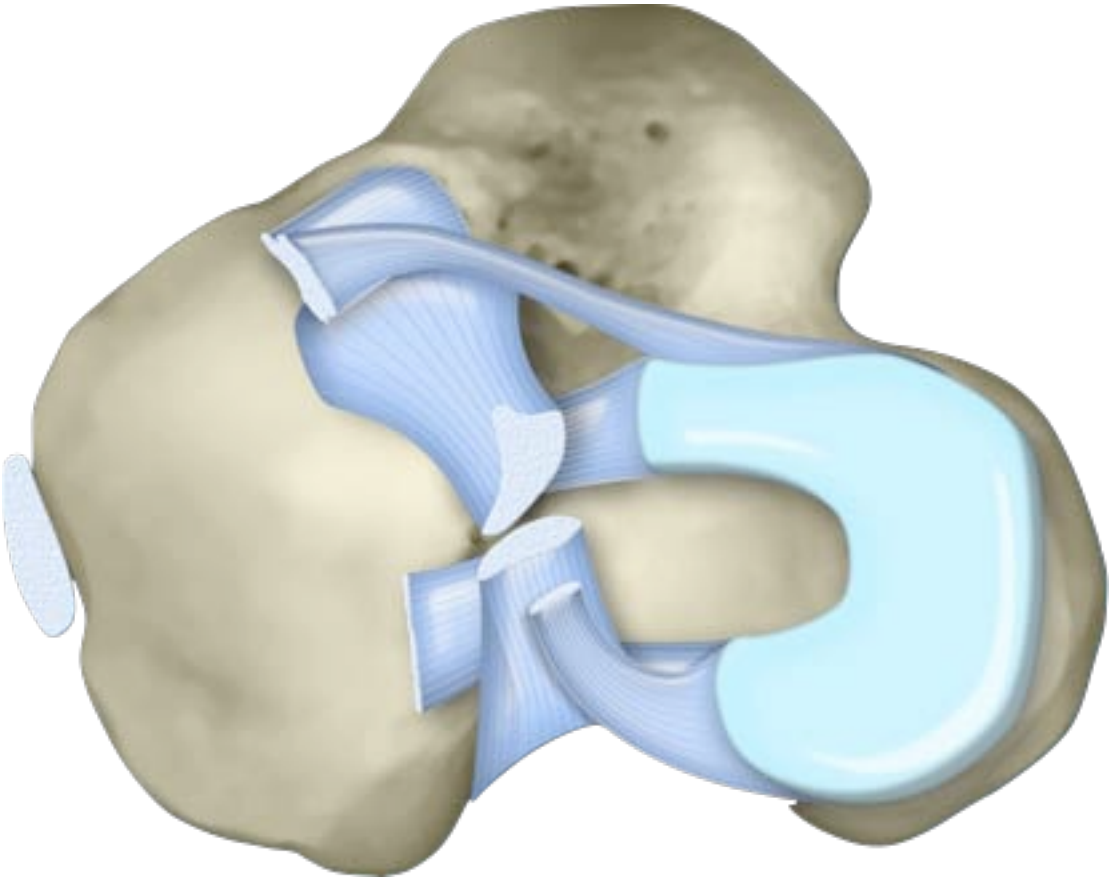

Figure 1-4. Total meniscectomy. The entire medial meniscus has been excised leaving the tibial plateau exposed.

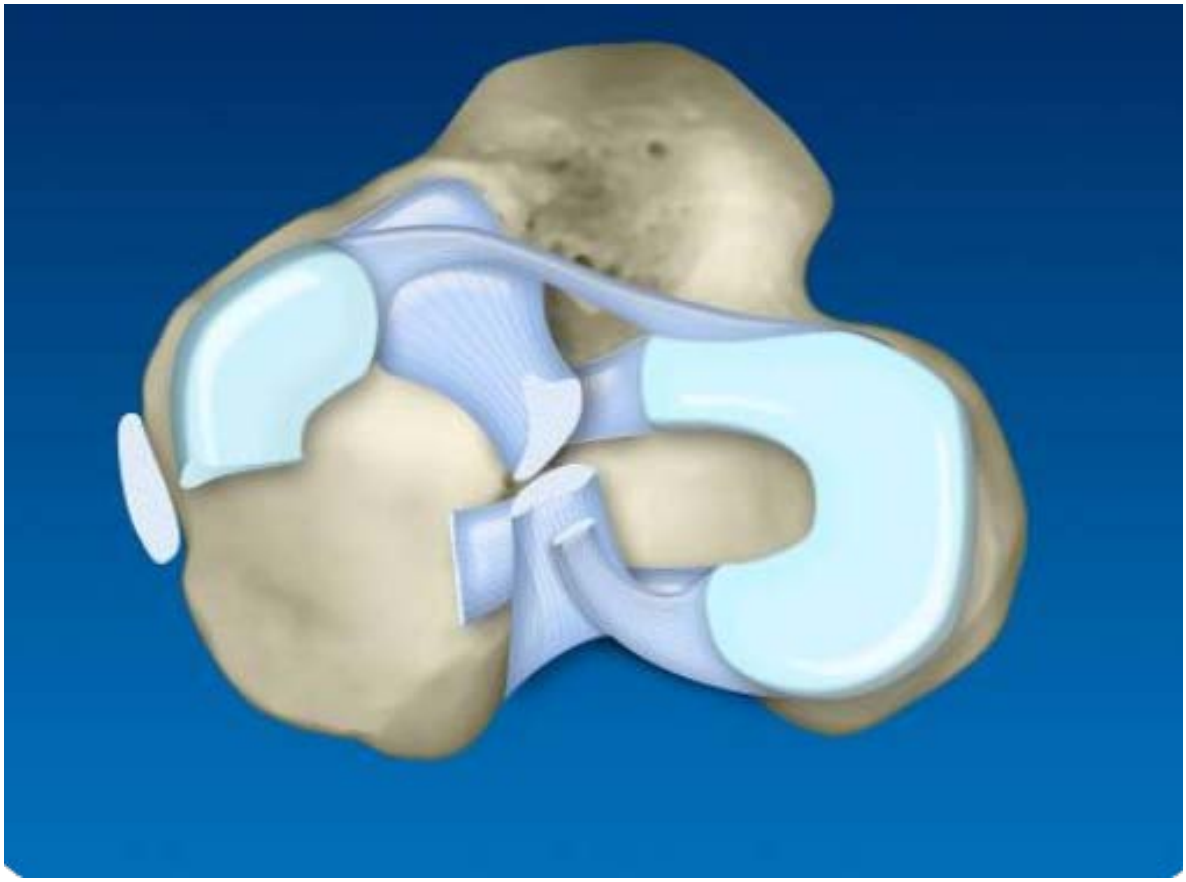

Figure 1-5. Caudal pole hemimeniscectomy. The caudal pole of the medial meniscus has been excised.

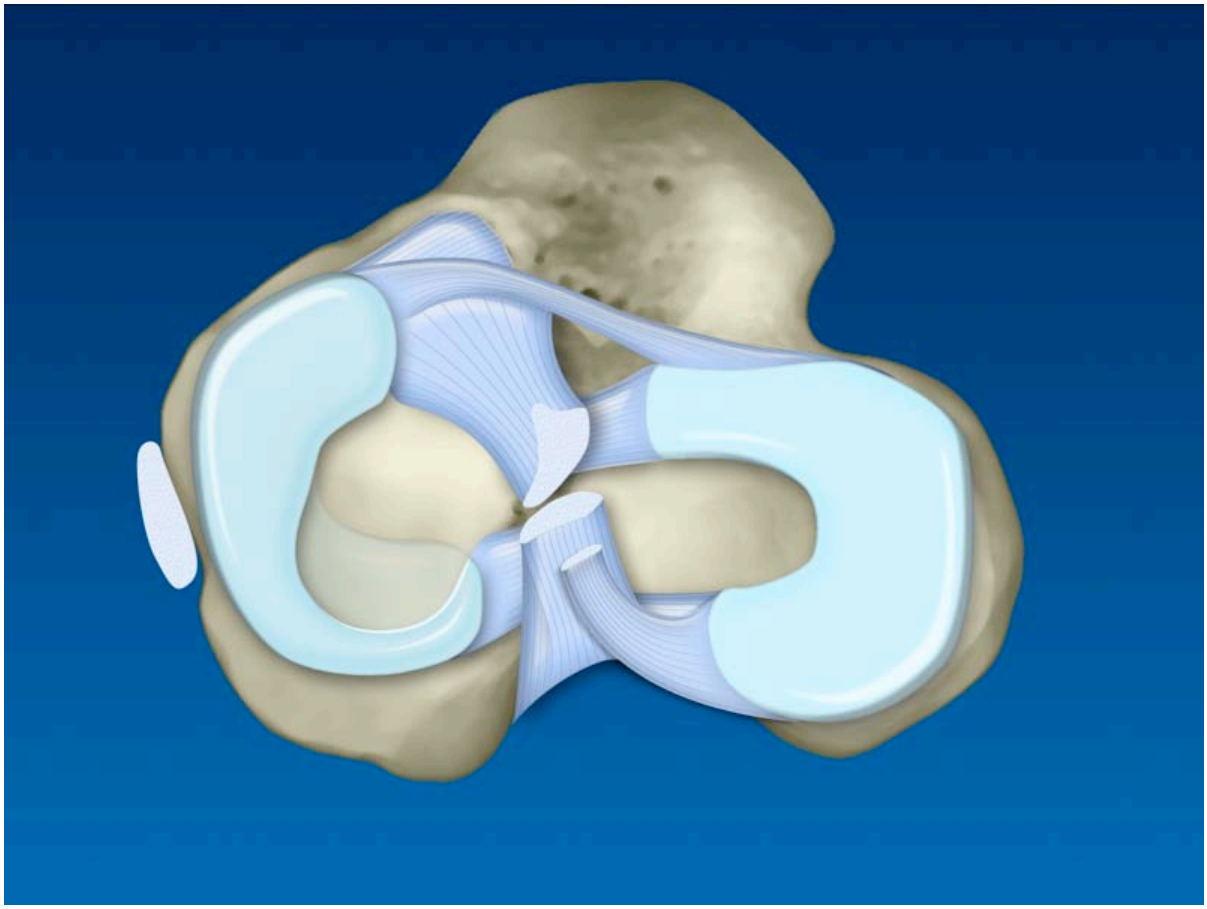

Figure 1-6. Partial meniscectomy. The axial portion of the meniscus which was damaged has been removed leaving a smooth arc of tissue and the meniscotibial ligaments intact.

CHAPTER 2
CONTACT MECHANICS OF SIMULATED MENISCAL TEARS IN CADAVERIC DOG STIFLES

Introduction

Meniscal damage is a common sequela to cranial cruciate ligament (CrCL) insufficiency in dogs.[53, 54, 57, 78] Meniscal injuries are thought to occur because of the inherent instability of the CrCL-deficient stifle.[53, 54, 57] Increased cranial translation and internal rotation of the tibia result in abnormal shear and compressive forces on the medial meniscus.[109-111] The caudal pole of the medial meniscus is a secondary stabilizer in the CrCL deficient stifle, acting as a wedge to resist caudal displacement of the medial femoral condyle.[45] These abnormal forces on the medial meniscus may result in injury to the caudal pole of the medial meniscus.[110]

Meniscal lesions have been categorized into 5 types based on appearance of the tear: radial, vertical longitudinal, horizontal, flap, and complex.[112] Variations of each of these tears are common in dogs. We studied the radial, vertical longitudinal, flap and complex tears and a common variation of the vertical longitudinal tear, the “bucket handle”, which is a vertical longitudinal tear with axial displacement of the torn portion of the meniscus. The horizontal tear was included as a component of the complex tear.

Many factors reportedly play a role in the development of degenerative joint disease (DJD) and abnormalities in load distribution have been considered a major factor in the pathogenesis of degenerative changes.[113] The meniscus is a weight-bearing structure that distributes load transmitted through the stifle.[30, 33] Menisci are composed of circumferential collagen bundles which transform axial force into hoop tension when the joint is loaded.[13, 26, 114] Complete radial disruption of the circumferential collagen bundles renders the meniscus dysfunctional and alters the

contact mechanics of the stifle.[29] Impairment of the normal contact mechanics of the femorotibial joint results in cartilage damage and the development of DJD.[113] Evaluating the effect different types of meniscal tears have on stifle contact mechanics may help elucidate the mechanism of cartilage degeneration secondary to meniscal injury.

Although transection of the meniscus is known to alter stifle contact mechanics[29] to our knowledge, the effects of specific types of meniscal tears on stifle contact mechanics has not been reported. Specifically, whether certain meniscal tears conserve a level of meniscal function is largely unknown. Information concerning conservation of meniscal function may play an important role in the decision making process when addressing meniscal pathology. Some meniscal lesions observed with CrCL insufficiency do not completely disrupt the circumferential collagen bundles, but instead split and separate the collagen bundles possibly preserving some degree of function.[39] If alterations in contact mechanics are negligible in specific meniscal tears, non-surgical treatment or meniscal repair may be considered in dogs. Therefore, the development of an ex-vivo canine limb model for studying the contact mechanics of meniscal tears and subsequently testing the ability of the meniscal repair to restore the normal contact mechanics is warranted.

Our purpose was to characterize and compare the changes in medial compartment femorotibial cartilage contact mechanics associated with 5 types of meniscal tears created in the caudal portion of the medial meniscus. We hypothesized that with increasing disruption of the structure of the medial meniscus, the contact area will decrease and peak contact pressure will increase in the medial compartment of the stifle.

Materials and Methods

Limb Specimens

Pelvic limb pairs were collected from 12 adult dogs (3 female, 9 male) with a mean body weight of 28.8 kg (range, 20.2 -37.8 kg) euthanatized for reasons unrelated to this study. Breeds were: Pit Bull Terrier (4), mixed breed dog (4) Chow Chow (2), and Char Pei (2). Limbs were harvested by coxofemoral disarticulation and frozen at -20° C. All limbs were determined to be free of macroscopic stifle pathology as was observed during specimen preparation:

Specimen Preparation

Limbs were thawed overnight at ~ 4.5 °C and the soft tissues were removed while preserving the stifle joint capsule. The femur and the tibia and fibula were transected 10 cm proximal and distal to the stifle joint line, respectively. The longitudinal axis of the tibia was positioned at an ~70° angle to the ground and potted in polymethylmethacrylate (PMMA). The femur was similarly potted in PMMA at a 90° angle. Specimens were then wrapped in saline (0.9% NaCl) solution soaked towels and frozen at -20° C.

Potted specimens were thawed to room temperature while remaining moist and wrapped in saline soaked towels. Stifle inspection, creation of meniscal lesions and sensor placement were performed via arthrotomy. The joint capsule was transected horizontally on the medial circumference of the stifle at the level of the tibial plateau. Arthrotomy was initiated medial to the patellar tendon and extended caudally until the insertion of the caudal cruciate ligament on the tibia could be observed. The medial collateral ligament (MCL) was transected near its femoral origin leaving sufficient tissue for suturing and preserving the attachment of the medial meniscus to the MCL. The

MCL was transected a second time near its tibial insertion leaving sufficient tissue for suturing. The joint was inspected and rejected from the study if preexisting joint pathology was detected.

Model of Meniscal Tears

Simulated tear types were radial, vertical longitudinal, non-reducible bucket handle, flap, and complex (Figure 2-1). The bucket handle tear was a variation of the vertical longitudinal tear with the axial border displaced cranially (Figure 2-1D). In this study, the structure of the axial portion of the bucket handle tear was disrupted rendering the axial portion non-reducible. A reducible bucket handle tear was not created. A horizontal tear was not performed in isolation but was created as part of the complex tear (Figure 2-1F).

Testing was performed on paired limbs and each pair of limbs was tested for every meniscal condition. Tear types were created alternating between right and left limb so that every tear type was performed in both right and left limbs throughout the study. Control data was collected from every limb (Figure 2-1A). Meniscal lesions were created in series with loading of the stifle and recording of a contact map occurring after creation of each meniscal lesion and before proceeding to the next tear type.

Radial and complex tears were created sequentially in the same limb. First, radial tears were created in the axial margin of the medial meniscus by making 3 radial incisions ~3 mm apart. The incisions were made between the MCL and the caudal meniscotibial ligament and extending ~25% of the width of the meniscus (Figure 2-1B). The complex tear was created in the same meniscus after data collection from the radial tear. To simulate the complex tear, multiple horizontal incisions were created in the caudal pole of the medial meniscus (Figure 2-1F). A needle holder was used to crush

the meniscal tissue. The shape and structure of the meniscus were disrupted to reproduce the gross appearance found clinically in complex tears.

Vertical longitudinal, non-reducible bucket handle, and flap tears were all created consecutively in the contralateral stifle. A full thickness, 6-8 mm long incision extending from the caudal meniscotibial ligament to the MCL was made in the peripheral, vascular one fourth of the meniscus,[115] termed the red zone, to simulate the vertical longitudinal tear (Figure 2-1C). After data collection from the vertical longitudinal tear, the non-reducible bucket handle tear was created by crushing the axial portion of the former tear with a needle holder and displacing the axial portion cranially (Figure 2-1D). Disruption of the axial meniscal tissue inhibited the axial portion from returning to its original position, creating a non-reducible bucket handle tear. After data collection, the caudal attachment of the "handle" was transected, creating a flap tear (Figure 2-1E).

Biomechanical Testing

Instantaneous contact area (CA) and peak contact pressure (PCP) measurements were recorded from a piezo-resistive pressure sensing system (Tekscan Inc., South Boston, USA). The sensors used were 30.9 mm in length x 12.0 mm in width with a thickness of 0.08 mm. Each sensor had 6 rows and 15 columns of sensing elements providing 90 sensels. The sensor had a pressure sensitivity of 0.01 MPa and a pressure range of 0.5 - 30.0 MPa. Each new sensor was conditioned and calibrated according to the manufacturer's guidelines immediately before testing of each specimen.[116]

The medial joint compartment was accessed by applying a valgus and rotational force to the stifle made possible by the transection of the MCL. The sensor was gently manipulated into the space subjacent to the medial meniscus and advanced axially until the entire width of the sensor was within the joint space. The axial margin of the sensor

rested against the caudal meniscotibial ligament and the abaxial margin rested against the MCL. The sensor was grasped at its cranial and caudal edges to avoid damage during placement. After positioning the sensor, the MCL was repaired by suturing the MCL remaining on the medial meniscus to the portions of MCL remaining on the femur and tibia with a cruciate pattern. The suture was tightened until the MCL was in apposition but not tightened so much as to collapse the medial compartment of the stifle.

A femoral jig was fastened to the potted femur by screwing the jig into the PMMA until the jig was flush with the PMMA margin. The femoral jig, which mounted directly to the materials testing machine (Instron 8500, Instron Corp., Canton, MA), was designed to allow compression, varus/valgus, flexion/extension and internal/external rotation realignment of the stifle.

The jig-stifle construct was axially loaded on the materials testing machine. The jig was secured to the load cell with the potted tibia and fibula resting on the actuator. Once the stifle was positioned at a normal standing angle of 140° of flexion,[117] the jig was used to correct stifle varus or valgus angulation. After positioning, all of the hinges on the jig were locked to ensure that the stifle would be axially loaded during testing. Compression was applied to the joint until the compressive force equaled 150 N and a contact map (Figure 2-2) was then recorded by a custom designed pressure sensor (I-Scan, Tekscan Inc., South Boston, MA). A force of 150N was chosen because it represents the force of ~50% of the body weight of a 30kg dog. Mean peak vertical force of a dog at a trot is 30.0% - 74.7% of its body weight (mean, 55.5%).[118] After the contact map was recorded, the joint was unloaded and the meniscal tear was inspected.

If the configuration of the meniscal tear changed during loading, the data collected from that limb was eliminated.

Data Analysis

Statistical analysis was performed using software (SPSS 15.0 for Windows, SPSS, Chicago, IL). A 1-way repeated measures ANOVA was performed to evaluate differences in CA and PCP among the 6 meniscal conditions (control, radial, vertical longitudinal, non-reducible bucket handle, flap and complex). When statistically significant differences between meniscal conditions were detected, a pair wise multiple comparisons procedure (Bonferroni) was performed. For all statistical analyses performed, $P < .05$ was considered statistically significant.

Control (intact meniscus) data was collected from every limb. The control data for CA and PCP from each right and left limb of the pair were compared. For each pair of limbs, there was no significant difference between control data collected from the right or left limb for CA (P=1.00) or PCP (P=1.00). Because the control data collected from each pair of limbs was not significantly different, the mean value for the pair was calculated and used as the control group to which all other meniscal conditions were compared.

Results

If Twenty-four stifles (12 pair) were tested and each pair of stifles had contact maps recorded for the 6 different meniscal conditions: intact meniscus (control), radial, vertical longitudinal, non-reducible bucket handle, flap, and complex tears (Figure 2-2).

No significant difference was found (P= .075, power= .660) in CA between any of the meniscal conditions. No significant difference in PCP was found in comparisons between control and radial tear (P=1) or between control and vertical longitudinal tear

(P= .544) (Table 1). Non-reducible bucket handle, flap and complex tears caused more than a 45% increase in PCP relative to the control. Interestingly, there was no significant difference in PCP between flap, non-reducible bucket handle, and complex tears (P= 1). The location of PCP was not recorded.

Discussion

We found that non-reducible bucket handle, flap, and complex tears caused >45% increase in PCP in the medial compartment of the stifle. These results may eventually refine the approach to the treatment of meniscal injuries. Optimal treatment of meniscal lesions should alleviate stifle pain while preserving meniscal function. Efforts should be made to preserve or repair menisci with tears that do not impair normal stifle contact mechanics. Our results suggest that radial and vertical longitudinal meniscal tears have little effect on stifle contact mechanics. We also established contact maps for the 5 major types of meniscal tears that may provide insight into the mechanism of cartilage degeneration caused by these tears.

Neither CA nor PCP differed from control in stifles with radial or vertical longitudinal tears. We suspect that these 2 lesions maintained normal contact mechanics because of their location, the small degree of disruption of the circumferential collagen bundles, and the minimal displacement of the torn meniscal tissue. The radial tears transected only the axial 25% of the meniscus and the vertical longitudinal tear was created in the red zone but was not displaced. The peripheral portion of the medial meniscus, which is responsible for most of the load transfer in the stifle,[119] was preserved in these 2 lesions and resulted in near normal contact maps. In studies evaluating medial menisci from human cadavers, radial tears extending ≤50% of the meniscal width preserved some meniscal function and the meniscus retained its

ability to effectively contribute transfer load through the joint.[114, 120] Therefore, we speculate that the radial tears in our study which transected only 25% of the meniscal width would not have a significant effect on the function of the circumferential fibers in providing hoop tension during standing.

The radial tear did not cause a significant change in contact mechanics when compared with the control. Therefore, we suspect that non surgical treatment might be appropriate in dogs with similar, naturally occurring meniscal tears. Small incomplete radial tears can be effectively managed in people without surgical treatment.[120, 121] Nociceptive innervation of the meniscus does not extend into the axial portion of the meniscus and incomplete radial tears of that area should not be associated with meniscal pain.[24, 121] Furthermore, because a radial tear is oriented perpendicular to the collagen fiber orientation, these lesions may be less likely to propagate and become a more severe tear. However, inflammatory cytokines released secondary to the torn meniscus and abrasive effects of the torn meniscus may both lead to articular cartilage damage.[56, 122-124] Therefore, in-vivo testing is necessary to confirm the hypothesis that radial tears may not necessitate surgical treatment.

The vertical longitudinal tears were created in the red zone, and as such, may be amenable to repair. Biomechanical testing in human knees has demonstrated that as the stifle flexes and extends, the axial portion of a vertical longitudinal tear will displace cranially, putting the axial portion of the tear in danger of becoming crushed between the femoral condyles and the tibia.[114] The continued motion and crushing of the meniscal tissue may cause progression of a simple tear such as a vertical longitudinal or bucket handle to a complex tear because of the chronic femorotibial subluxation. Our

results showed that bucket handle and flap tears cause abnormalities in contact mechanics. Therefore, consideration should be given to performing a meniscal repair to prevent the progression from a benign tear to a more severe tear with respect to contact mechanics. Further testing is required to determine the character of progression of meniscal tears. Meniscal tears amenable to repair are rare and, in our experience, more common with functional partial CrCL rupture.

Among the measured variables for contact mechanics, only PCP was significantly different in non-reducible bucket handle, flap, and complex tears compared with control measurements. Because articular damage occurs at the area of PCP during femorotibial contact, increased PCP is likely responsible for degenerative changes in the articular surface of the human knee.[119] We suspect that the non-reducible bucket handle, flap and complex tears are the most destructive meniscal tears leading to DJD because they cause the greatest increase in PCP. We suspect that these tears caused an increased PCP because of the destruction of circumferential bundles of the meniscus. Palpably, the meniscal tissue in the complex tear was soft which we ascribed to stretching and separation of the collagen bundles, negating effective generation of hoop stresses in the affected meniscus. In the non-reducible bucket handle and flap tears, the axial portion of the torn meniscus was displaced cranially and crushed, disrupting the circumferential collagen bundles. We suspect that both the displacement of tissue and the disruption of the circumferential collagen bundles led to the increase in PCP by removing the ability of the meniscus to generate normal hoop stresses. Because the menisci that had complex, non-reducible bucket handle and flap tears did not maintain the meniscus' load bearing function, we recommend that these

lesions should be debrided. Consideration should be given to repairing reducible bucket handle tears if located within the vascular zone of the meniscus.

Limitations

The major limitation of our study is the simulation of meniscal tears in normal cadaveric menisci. Simulation of tears is of most concern for tears thought to be of a chronic nature, mainly, the complex tear. The creation of this tear type was designed to simulate the gross appearance of a complex meniscus as seen clinically. The tissue was crushed until it was palpably soft as is found in patients. Because the microstructural degradation caused by different meniscal tears is unknown, we focused on simulating the observable geometric and morphologic changes of torn menisci. This same limitation applies to the other simulated tears; however, simulated tears have been used extensively in research of meniscal tears in both human and animal specimens.[114, 125]

A second limitation is the use of a stable stifle with intact CrCL in this model. Meniscal tears without concurrent rupture of the CrCL are rare in dogs.[126] We chose not to transect the CrCL in order to isolate the effects of the meniscal tears on contact mechanics. Transection of the CrCL impairs the normal contact mechanics,[29] and therefore would not allow evaluation of the meniscal tear itself. Additionally, in a clinical setting, meniscal tears will be treated concurrent with stifle stabilization. The effect of CrCL deficiency on contact mechanics should be eliminated by the technique used for joint stabilization.[127] We believe that leaving the CrCL intact in this study did not alter our findings and instead allows recognition of altered mechanics caused by the different meniscal tear types.

The Tekscan system is simple, reproducible and reliable[128] but is not without limitations. The custom designed canine sensor is thin (0.08 mm) but this thickness may still alter contact area and pressure measurements. The advantages and limitations of the custom designed canine sensor have been reported.[127] Notably, the joint capsule must be transected to place the sensor. In our model, only the MCL was repaired, the joint capsule was not. Whereas joint capsule disruption may affect the contact mechanics, the results obtained were compared to similarly prepared stifles, minimizing the impact of joint capsule disruption.

Summarily, radial and vertical longitudinal tears did not cause statistically significant changes in CA or PCP whereas non-reducible bucket handle, flap, and complex tears caused >45% increase in PCP. Menisci with non-reducible bucket handle, flap and complex tears no longer perform their load bearing function and should be debrided. Although the radial and vertical longitudinal tears do not alter the contact mechanics of the joint, we are unable to determine how these tears will respond clinically if left unattended. We suspect that abnormal forces through the joint will not be present and will not be a cause for the development of DJD; however, DJD may still develop because of other factors such as the release and induction of inflammatory mediators. Additionally, clinical signs including pain, lameness, and clicking may still occur.[49] Therefore, clinical testing is required before recommendations are made on specific treatments of meniscal tears.

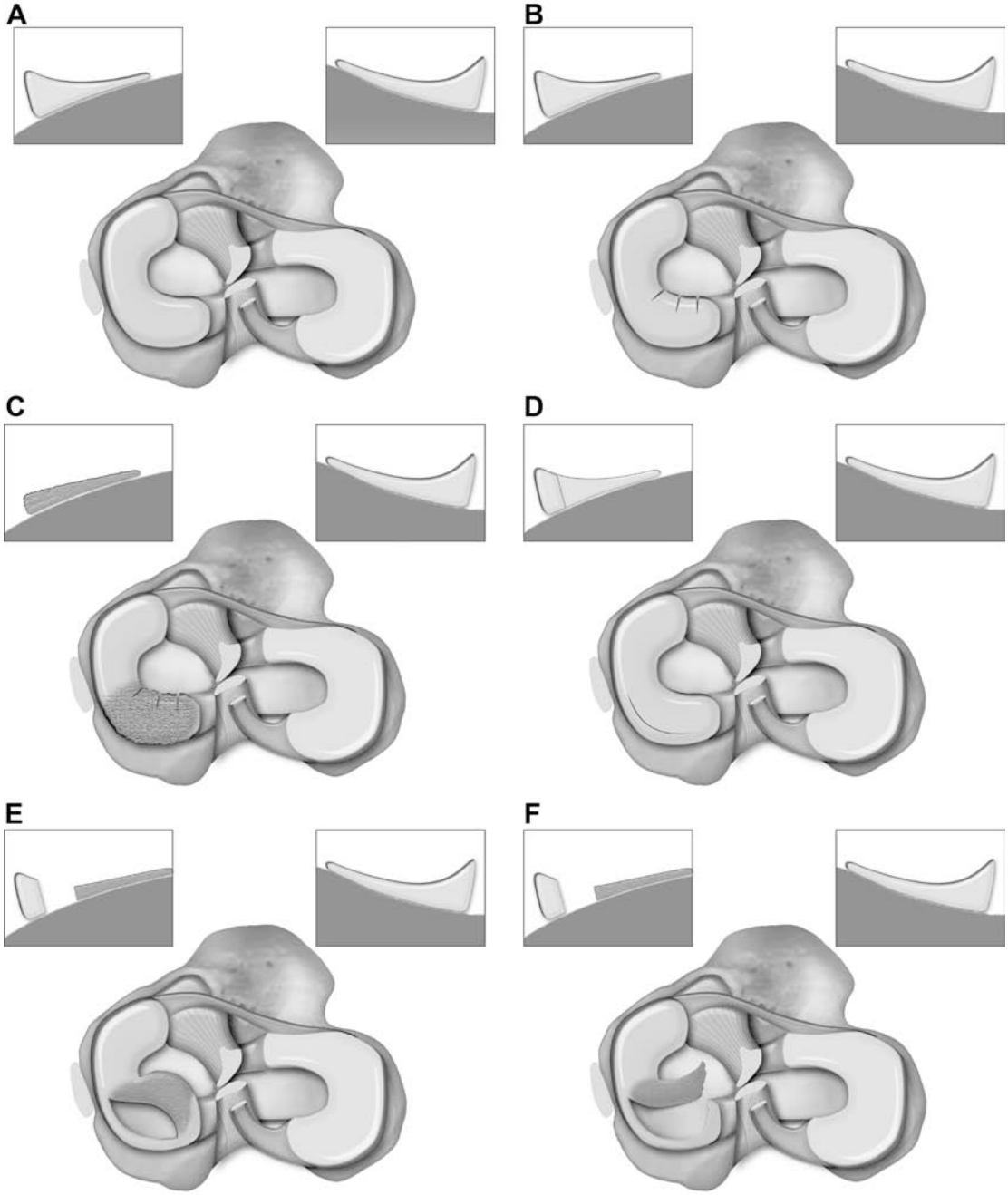

Figure 2-1. A right tibial plateau with illustrations of the 6 meniscal conditions evaluated in this model A) Control; B) Radial; C) Vertical Longitudinal; D) Non-reducible bucket handle; E) Flap; and F) Complex.

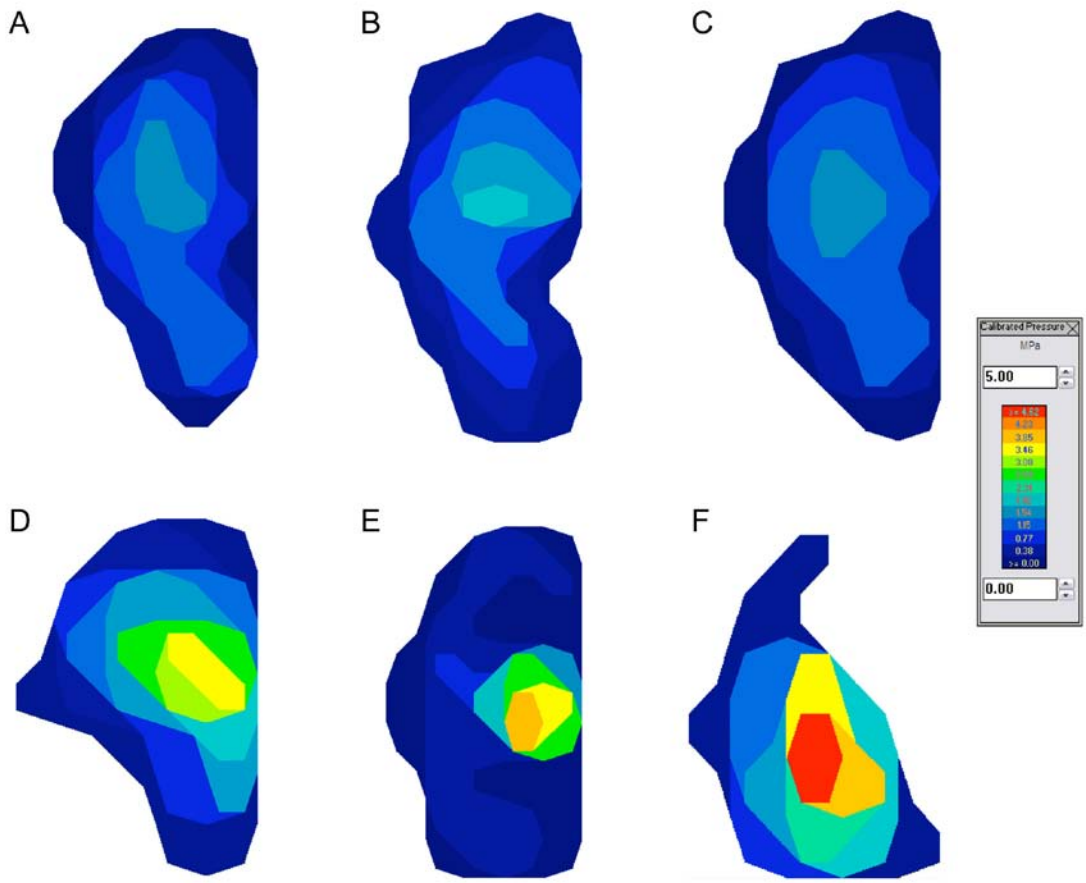

Figure 2-2. Contact maps acquired from stifles for each meniscal condition A) Control; B) -Radial; C) Vertical Longitudinal; D) Non-reducible bucket handle; E) Flap; F) and Complex. Calibration scale (on right) indicates the pressure (MPa) designated by each color on the contact maps, increasing from blue to red.

Table 2-1. Mean ± SD Contact Area and Peak Contact Pressures in Control Stifles and 5 Meniscal Tears.

Meniscal condition	Contact area (mm^2)	Peak contact pressure (MPa)
Control	123.38± 18.45	3.13 ± 0.61
Radial	126.17 ± 21.15	2.97 ± 0.56
Vertical longitudinal	123.08 ± 23.95	3.67 ± 1.26
Non-reducible bucket handle	120.42 ± 24.27	4.62 ± 1.08*
Flap	118.92 ± 35.00	5.08 ± 1.10*
Complex	106.08 ± 23.72	4.92 ± 0.98*

* Indicates a statistically significant difference ($P < .05$) when compared with control

CHAPTER 3
A COMPARISON OF CONTACT MECHANICS OF THREE MENISCAL REPAIR TECHNIQUES AND PARTIAL MENISCECTOMY IN CADAVERIC DOG STIFLES

Introduction

Dogs with cranial cruciate ligament (CrCL) insufficiency frequently sustain damage to the caudal pole of the medial meniscus.[57, 78] Historically, total meniscectomy was the recommended treatment for meniscal tears in both dogs and people.[78, 129] The resection of the torn meniscus was found to ameliorate pain and improve short term function.[78] Subsequent studies showed that meniscectomy accelerated the progression of degenerative joint disease (DJD) in the CrCL-deficient stifle and questioned the widespread clinical use of this technique.[37, 42, 63] Although total meniscectomy and segmental meniscectomies, such as caudal pole hemimeniscectomy, result in supraphysiologic intra-articular contact pressures[29, 43] and articular cartilage damage,[33, 37, 42, 125, 130] meniscectomies are still commonly performed in dogs.[77] Most surgeons advocate conservative excision of the damaged meniscal tissue by performing a partial meniscectomy when appropriate.[131] The peripheral rim of meniscal parenchyma remaining following partial meniscectomy retains some capacity to generate hoop tension and transmit load across the stifle.[43, 79] It has been recently reported that the remaining meniscal function following partial meniscectomy depends on the extent of meniscal resection.[79] The resection of an abaxial bucket handle tear involving the vascularized region of the meniscus eliminates most of the hoop tension of the meniscus and its load bearing function. In an attempt to preserve meniscal function and mitigate the progression of DJD, these tears are often repaired in human patients.[132, 133] Although infrequently performed, meniscal repair has been described in dogs.[87-90, 93, 134-136] Evaluating the ability of meniscal repair to restore meniscal function as compared to

partial meniscectomy would be important to help determine whether or not meniscal repair should be considered in dogs.

The benefits of meniscal repair are not realized if the repaired meniscal tissue is of poor quality or configuration and fails to function as an intact meniscus.[137] Torn meniscal tissue that has lost its normal structure and mechanical function is unlikely to regain normal function.[138] We recently performed a study which evaluated the mechanical behavior of meniscal tears in dogs[139] We found that non-reducible bucket handle, flap and degenerative tears each caused an approximately 45% increase in peak contact pressure.[139] Although the meniscal parenchyma of degenerative tears and flap tears is macerated, necessitating resection of the damaged tissue, vertical longitudinal tears and bucket handle tears occurring in the red zone with healthy meniscal tissue may be amenable to repair.[139, 140] Repair of suitable meniscal lesions in human specimens has been shown to improve joint contact mechanics.[43, 141] We suspect that repair of reducible bucket handle tears occurring in the red zone of the medial meniscus in dogs could restore the biomechanical function of the meniscus. To the authors' knowledge, the effect of meniscal repairs on the contact mechanics of the dog stifle has not been reported. The purpose of this study was to determine the ability of vertical, horizontal, and cruciate suture meniscal repairs to restore normal contact mechanics to dog stifles with simulated bucket handle meniscal tears and the contact mechanics resultant from the three repair techniques were also compared to the contact mechanics resultant from partial meniscectomy. Our hypothesis was that vertical, horizontal and cruciate suture meniscal repairs would restore normal contact mechanics

to dog stifles with simulated bucket handle meniscal tears while partial meniscectomy would have a detrimental effect on contact mechanics.

Materials and Methods

Twenty-four pelvic limbs were collected from six female and six male adult mixed breed dogs which were euthanized for reasons unrelated to this study. The mean body weight was 29.7 + 3.7 kg and ranged from 23 to 36 kg. All limbs were harvested by coxofemoral disarticulation and frozen at -20° C. This study was approved by our institution's laboratory animal care and use committee.

Specimen Preparation

The limbs were thawed overnight at approximately 4.5 °C. After thawing, the soft tissues were removed while preserving the stifle joint capsule. The femur and tibia and fibula were transected 4 cm proximal 6 cm distal to the stifle joint line, respectively. The tibia was potted in polymethylmethacrylate. The specimens were then wrapped in saline soaked towels and frozen at -20° C.

The potted specimens were thawed to room temperature while wrapped in saline soaked towels for one hour prior to mechanical testing. Stifle inspection, creation of meniscal lesions, meniscal repairs and sensor placement were performed via circumferential arthrotomy. The joint capsule was incised horizontally along the medial side of the stifle at the level of the tibial plateau. The arthrotomy was initiated medial to the patellar tendon and extended caudally until the insertion of the caudal cruciate ligament on the tibia could be visualized. The medial collateral ligament was transected near its tibial insertion leaving sufficient tissue for suturing. The attachment of the medial meniscus to the medial collateral ligament was preserved. The medial collateral ligament was transected a second time near its femoral origin leaving sufficient tissue

for suturing. The stifle was inspected and rejected from the study if preexisting joint pathology was detected.

Contact maps were recorded in each stifle for three different conditions: control (intact meniscus), bucket handle tear, and meniscal treatment. After the control contact map was recorded, a bucket handle tear, defined as cranial displacement of the axial segment of a vertical longitudinal tear, was created (figure 3-1B). The bucket handle tear was created by making a full thickness incision in the peripheral 25% of the meniscus from the caudal meniscotibial ligament to the level of the medial collateral ligament. A loop of suture was passed around the axial segment of the incised meniscus. The suture was passed cranially through the intercondylar notch to displace the axial segment cranially. The suture was then secured to the cranial joint capsule to fix the position of the displaced segment.

After the bucket handle contact map was recorded, one of four different meniscal treatments was performed: vertical suture repair, horizontal suture repair, cruciate suture repair or partial meniscectomy (figure 3-1). The twenty-four limbs were randomly assigned into one of the four meniscal treatment conditions such that each of the four meniscal treatments was performed on six of the limbs. All of the suture repairs were performed using Meniscus Repair Needles (Arthrex, Naples FL). The Meniscus Repair Needles are two flexible, stainless steel needles swedged onto each end of a 96.5 cm strand of 2-0 Fiberwire (Arthrex, Naples FL).

The vertical suture repair was performed by positioning the first needle just distal to the meniscal tear on the axial segment. The needle was advanced through the axial segment and the tear was assessed for adequate apposition. Once the margins of the

tear were apposed, the needle was advanced through the peripheral segment and pulled through the meniscus. The second needle was placed directly proximal to the first pass of the suture in the proximal meniscal segment. This needle was advanced engaging the peripheral segment of the tear. The suture was knotted on the peripheral border of the meniscus. The process was repeated, placing a second vertical suture approximately 3 mm from the first (figure 3-1C).

The horizontal suture repair was performed by placing the first Meniscus Repair Needle (Arthrex, Naples FL) one third of the distance from the lateral commissure of the tear on the axial segment of the meniscus. The needle was advanced and the tear was assessed for apposition. Once the margins of the tear were apposed, the needle was advanced through the peripheral segment and pulled through the meniscus. The process was repeated with the second needle positioned one third of the distance from the medial commissure of the tear on the axial segment of the meniscus. The suture was knotted on the peripheral border of the meniscus. The result was one suture oriented parallel to the meniscal tear (figure 3-1D).

The cruciate suture repair was performed by placing the first Meniscus Repair Needle (Arthrex, Naples FL) one third of the distance from the lateral commissure of the tear on the axial segment of the meniscus. The needle was advanced and the tear was assessed for apposition. Once the margins of the tear were apposed, the needle was advanced through the peripheral segment and pulled through the meniscus. The second needle was positioned on the proximal portion of the meniscal tear, approximately one third of the distance from the medial commissure of the tear. This needle was advanced engaging only the peripheral segment of the tear. The suture

was knotted on the peripheral border of the meniscus. The process was reversed and repeated, creating a cruciate suture with two knots on the peripheral border of the meniscus (figure 3-1E).

The partial meniscectomy was performed by incising the meniscus axially from the commissures of the tear using a #11 scalpel blade in a smooth arc cranially and caudally, excising the axial three quarters of the meniscus and leaving the periphery intact (figure 3-1F).

Instantaneous contact area (CA), mean contact pressure (MCP) and peak contact pressure (PCP) measurements were recorded using a piezo-resistive pressure sensing system (Tekscan Inc., South Boston, USA) for control, bucket handle tear, and meniscal treatment conditions for each stifle. The sensors used in this study were 30.9 mm in length by 12.0 mm in width and a thickness of 0.08 mm. The sensor had a pressure sensitivity of 0.01 MPa and a pressure range of 0.5 to 30.0 MPa. A new sensor was used for each stifle. Each sensor was conditioned and calibrated according to the manufacturer's guidelines immediately prior to testing of each specimen.[116] The sensor was positioned in the medial joint compartment by applying a valgus and rotational force to the stifle made possible by the transection of the medial collateral ligament. The sensor was then gently manipulated into the space subjacent to the medial meniscus. The sensor was advanced axially until the entire width of the sensor was within the joint space. The axial margin of the sensor rested against the caudal meniscotibial ligament and the abaxial margin rested against the medial collateral ligament. The sensors were only grasped along the cranial and caudal margins to prevent damaging the sensing units. After positioning the sensor, the medial collateral ligament was repaired by

suturing the medial collateral ligament remaining on the medial meniscus to the portions of medial collateral ligament remaining on the femur and tibia with 2-0 polypropylene in a cruciate pattern. The suture was tightened until the medial collateral ligament was apposed without collapsing the medial compartment of the stifle.

A 6.3mm diameter Steinmann pin was drilled through the femur in a craniocaudal direction parallel to the joint line of the stifle approximately 1cm distal to the femoral osteotomy. The pin was secured in a femoral jig. The femoral jig, which mounted directly to the materials testing machine (MTS, Eden Prairie, MN, USA), was designed to allow compression, varus/valgus, flexion/extension and internal/external rotational realignment of the stifle (figure 3-2). The jig-stifle construct was loaded on the materials testing machine. Once the stifle was positioned at a normal standing angle of 135° + 5° of flexion,[117] the jig was used to correct stifle varus or valgus angulation. After positioning, the jig was locked to ensure that the stifle would be axially loaded during testing. The potted tibia rested on a custom made sliding platform to allow for rotation, craniocaudal translation and mediolateral translation to permit minor adjustments and ensure axial loading. Each stifle was loaded with 150 N of force and the contact map was recorded.

Data Analysis

Statistical analysis was performed using SigmaStat 3.0 for Windows (SPSS, Chicago, IL). One-way repeated measures ANOVA was used to evaluate differences in CA, MCP and PCP among the three meniscal conditions (control, bucket handle tear, meniscal treatment). When statistically significant differences between meniscal conditions were detected, a Tukey pairwise multiple comparisons procedure was performed. In order for the data to be compared between treatment groups and to

account for anatomic variation, a normalized CA, MCP and PCP were calculated by dividing the treatment variable by the control data obtained from the same specimen. A result of 1.00 indicated that the treatment value and the control value were the same for the parameter evaluated. A one way analysis of variance or Kruskal-Wallis one way analysis of variance on ranks was performed for each parameter. When statistically significant differences between meniscal conditions were detected, a Tukey pairwise multiple comparisons procedure was performed. For all statistical analyses performed, $P < 0.05$ was considered statistically significant.

Results

Twenty four stifles underwent biomechanical testing. Each stifle had a contact map recorded for each of the meniscal conditions: control, bucket handle tear and meniscal treatment. From each contact map, CA, MCP and PCP were recorded and compared (Table 3-1). After creating bucket handle tears, the stifles had significantly smaller CAs ($P<0.001$) and significantly higher MCPs ($P<0.001$) and PCPs ($P<0.001$) than control stifles. No significant differences were detected when comparing the contact mechanics of stifles with repaired menisci to control stifles (CA $P=0.437$, power=1.000; MCP $P=0.872$, power=1.000; PCP $P=0.690$, power=1.000). Stifles with a partial meniscectomy had significantly lower CAs ($P=0.019$) and higher MCPs ($P=0.012$) and PCPs ($P<0.001$) than control stifles. No significant differences were detected between stifles with a partial meniscectomy and stifles with a bucket handle tear (CA $P=0.427$, power=0.649; MCP $P=0.085$, power=0.744; PCP $P=0.077$, power=0.988).

When comparing the efficacy of the four meniscal treatments to restore normal contact mechanics using normalized data, no significant differences were detected in

CA restored between horizontal, vertical or cruciate suture repairs (P=0.97, P=0.97, P=1.00, respectively; power=0.653) (table 3-1). Stifles which had a horizontal suture repair had a significantly greater percentage of CA restored than stifles which had a partial meniscectomy (P=0.023). Stifles which had cruciate repair and vertical suture repairs did not have a statistically different percentage CA restored than stifles which had a partial meniscectomy (P=0.057, power=0.653 and P=0.057, power=0.653, respectively). All three suture repair techniques were found to result in MCPs that were significantly closer to MCPs from control stifles than in stifles which had a partial meniscectomy (P=0.001). No significant differences were found in percent MCP restored when comparing the horizontal, vertical or cruciate suture repair techniques (P=1.000, power= 1.000). When comparing the efficacy of treatment with respect to restoring normal PCP, all three suture repair techniques were found to result in PCPs closer to those in control stifles than in stifles which had a partial meniscectomy (P=0.004). No significant differences were detected between percent PCP restored when comparing the horizontal, vertical or cruciate suture repairs.

Discussion

In this cadaveric study, we found that repair of a simulated bucket handle tear located in the vascular zone of the caudal pole of the medial meniscus reestablished the normal load bearing function of the meniscus in a stifle with an intact CrCL. Our results support repairing selected bucket handle tears in the vascular zone of the meniscus rather than performing a partial meniscectomy. Removal of the axial portion of the torn meniscus did not improve the tibiofemoral contact mechanics when compared to stifles with bucket handle tears. Conserving meniscal tissue would be advantageous as degeneration of femoral and tibial articular cartilage has been shown to be proportional

to the amount of meniscal parenchyma excised.[37] Our study is in agreement with previous studies that showed an extensive partial meniscectomy should be avoided if possible.[79, 119] In selected cases, suturing meniscal tears involving the vascular zone may be a more conservative approach, potentially mitigating the progression of DJD. Further studies need to be performed to establish the efficacy of meniscal repair in dogs and to define appropriate selection criteria.

The contact mechanics obtained for each of the meniscal repair techniques tested in this study were mechanically superior to partial meniscectomy. The results from this study should be interpreted in light of the ex vivo study design. To simulate the bucket handle tears, meniscal tissue was incised and displaced, but not crushed or macerated. Therefore, when the meniscal tear was repaired, normal parenchyma was sutured to normal parenchyma. The sutures effectively maintained the axial portion of the torn meniscus in apposition, restoring normal meniscal geometry, which is essential for its load bearing function.[119] Unfortunately, the meniscal parenchyma of the axial portion of bucket handle tears in dogs with CrCL insufficiency often has disruption of normal structure and material properties because the meniscus has been damaged from chronic impingement between the femoral and tibial condyles.[26, 72, 142] In a previous study, we found that simulated non-displaced bucket handle (vertical longitudinal) tears created in normal meniscal tissue did not disrupt normal stifle contact mechanics, but crushing the parenchyma of bucket handle tears resulted in an increase in PCP.[139, 140] The results of the current study corroborate our previous findings and suggest that meniscal repairs should only be considered for vertical longitudinal tears or acute

bucket handle tears because the material properties and the geometry of the meniscus may be disrupted in chronic tears.[139, 140, 143, 144]

All three suture repair techniques that we tested reestablished normal tibiofemoral contact mechanics. No difference in PCP and CA was found among the repair techniques. To our knowledge, this is the first study comparing tibiofemoral contact pressures following horizontal, vertical and cruciate suture techniques. Vertical and horizontal suture repair of a peripheral vertical longitudinal tear have been evaluated in a cadaveric human study.[43] Both suture techniques reestablished normal PCP, while partial meniscectomy caused approximately a 65% increase in PCP. Similarly, we found that suture repairs in dogs reestablished normal PCP while partial meniscectomy caused an approximately 55% increase in PCP. Our contact mechanics data suggest that the three suture techniques equally reestablished the load bearing function of the meniscus. These results should be interpreted cautiously because other biomechanical factors such as fixation strength may be more relevant for determining which technique should be recommended in dogs. Several in vitro animal and human studies have shown that the vertical and oblique suture repairs display superior load to failure than horizontal repair.[145-148] Until further mechanical studies are performed on meniscal suture techniques in dog menisci we would recommend a vertical or cruciate suture repair.

Clinical Relevance

Our study cannot address the clinical efficacy of meniscal repair. Furthermore, our data do not provide information regarding which meniscal tears are suitable for repair in the clinical setting. In previous experimental studies performed in dogs, repair of tears involving the vascular zone of menisci healed.[90-93] In a study by Newman et al., tears

similar to our bucket handle tears were surgically created in dog stifles and underwent suture repair. Those dogs' menisci healed without leading to femoral or tibial articular cartilage damage.[92] Wyland et al. created peripheral meniscal tears in dogs which were not repaired.[130] These dogs developed stifle articular cartilage damage.[130] The results of these two studies imply that meniscal repair of surgically created bucket handle tears may protect the articular cartilage from damage. Further studies to assess the efficacy of meniscal repairs to alleviate pain and to potentiate successful healing need to be performed.

The results of our study should be interpreted cautiously, because of the variety of factors that influence meniscal healing, including inflammatory cytokines, growth factors, mechanical loading and zonal differences in vascularity, cell and tissue properties.[19, 27, 123] In our study we created the tears in the periphery of the meniscus because this location is considered ideal for meniscal healing following repair.[19] Axially located tears typically fail to heal due to a lack of vascularity and the small size of the torn fragment to be sutured. Another limitation of this study was the use of a stable stifle with an intact CrCL. Meniscal tears are often the result of CrCL insufficiency in dogs.[57, 78] We chose not to transect the CrCL in order to isolate the effects of the meniscal repairs. Transection of the CrCL impairs the normal contact mechanics,[29] and therefore would not allow evaluation of the effects of the meniscal tear itself. Additionally, we would recommend performing meniscal repair concurrent with stifle stabilization to reestablish normal kinematics and contact mechanics, while protecting the repaired meniscus. The Tekscan system used in this study is simple to use and yields reproducible and reliable data[128] but is not without its limitations. The custom

designed canine sensor is thin (0.08 mm) but this thickness may still alter contact area and pressure measurements. The advantages and limitations of the custom designed canine sensor have been previously reported.[127] We incised the joint capsule and medial collateral ligament in order to place the sensor but only the medial collateral ligament was repaired, not the joint capsule. While joint capsule disruption may affect the contact mechanics, the results obtained were compared to similarly prepared stifles, minimizing the impact of joint capsule disruption. Another limitation was that contact maps were recorded only from the meniscotibial interface. Material in contact with the femoral articular cartilage is a potential concern for causing focal increase in PCP and abrasion of the articular cartilage.[149] The effect of suture material contacting the articular cartilage of the femur warrants further exploration.

Conclusion

In conclusion, the three repair techniques evaluated in this study restored normal contact mechanics to the medial compartment of a stifle with a simulated medial meniscal bucket handle tear. Partial meniscectomy caused a 35% decrease in CA, a 57% increase in MCP and a 55% increase in PCP. In contrast, meniscal repair reestablished normal CA, MCP and PCP. Based on our results, consideration should be given to repairing peripheral tears involving the vascular zone if the parenchyma of the axial portion of the meniscus is normal. Partial meniscectomy should be considered for more axial tears and in case of abnormal torn meniscal tissue. Further work is needed to determine the optimal repair technique which should be used in clinically in dogs based on fixation strength and ease of application.

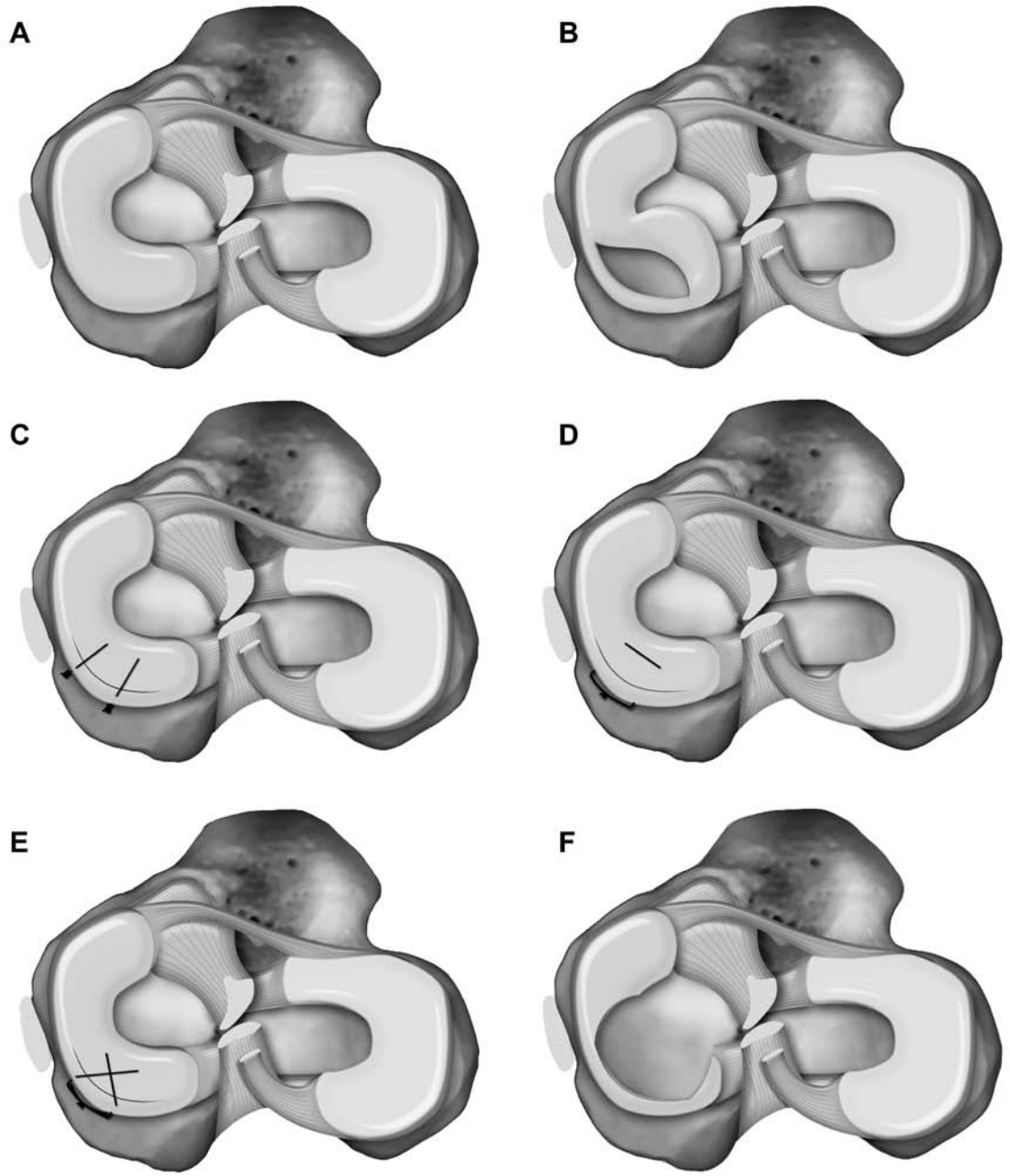

Figure 3-1. Illustration of right tibial plateau with each meniscal condition A) intact medial meniscus, B) simulated bucket handle tear, C) vertical suture repair, D) horizontal suture repair, E) cruciate suture repair, and F) partial meniscectomy.

Figure 3-2. Photograph of testing apparatus including femoral jig, potted stifle and Tekscan sensor positioned subjacent to medial meniscus.

Table 3-1. Mean ± standard deviation for contact parameters obtained from stifles in which treatments for medial meniscal bucket handle tears were evaluated.

Medial meniscal status	CA	MCP	PCP
Control	113.44 ± 12.93	0.88 ± 0.11	2.39 ± 0.69
Bucket Handle Tear	72.50 ± 6.32 (P<0.001)	1.20 ± 0.22 (P<0.001)	3.70 ± 1.40 (P=0.009)
Horizontal Suture Repair	107.67 ± 14.43(P=0.986)	0.94 ± 0.11 (P=0.999)	2.49 ± 0.70 (P=0.993)
Vertical Suture Repair	106.83 ± 10.38 (P=0.635)	0.91 ± 0.18 (P=0.862)	2.31 ± 0.64 (P=0.717)
Cruciate Suture Repair	110.33 ± 13.68 (P=0.487)	0.85 ± 0.17 (P=0.902)	2.38 ± 0.84 (P=0.858)
Partial Meniscectomy	70.17 ± 31.06 (P=0.019)	1.59 ± 0.57 (P=0.012)	4.45 ± 1.04 (P<0.001)

P values reported indicate differences obtained for medial meniscus status compared to control (P<0.05 considered statistically significant difference).

CHAPTER 4
CONCLUSION

The menisci are important structures in maintaining stifle health. The menisci play an important role in load-bearing which is predicated on the microanatomy of the menisci. The menisci are made of circumferential collagen bundles which transfer compressive stress to hoop strains. If the load bearing function of the meniscus is destroyed by transection of these circumferential collagen bundles or by meniscectomy, degenerative joint disease will ensue.[12, 29-31] Historically, meniscectomy was the primary treatment of choice for all meniscal tears.[1]

Meniscal tears are an important cause of stifle pain and dysfunction in dogs with CrCL insufficiency especially in the cranial cruciate ligament deficient stifle. Diagnosis of meniscal tears can be made in several ways including ultrasound, MRI, CT arthrogram or direct visualization of the meniscus by arthrotomy or arthroscopy. Because of increased severity of osteoarthritis in animals and people undergoing meniscectomy, attempts should be made to minimize resection of meniscal tissue during meniscal treatment. Partial meniscectomy is applicable if the axial portion of the meniscal tissue to be preserved is functional. Five main types of meniscal tears have been described. The effect each of these five tears had on contact area (CA) and peak contact pressure (PCP) were compared in Chapter 2.

Radial and vertical longitudinal tears did not cause statistically significant changes in CA or PCP. Non-reducible bucket handle, flap and complex tears caused >45% increase in PCP. Menisci with non-reducible bucket handle, flap and complex tears have decreased load bearing capabilities. Although the radial and vertical longitudinal tears do not alter the contact mechanics of the joint, we are unable to determine how

these tears will respond clinically if left unattended. We suspect that these tears would not result in abnormal force transmission through the stifle and would not contribute to the development of degenerative joint disease (DJD) by altering force transmission. DJD may still develop because of biologic factors such as the release and induction of inflammatory mediators. Additionally, clinical signs including pain, lameness, and clicking may still occur.[49] Therefore, clinical studies are required before recommendations can be made regarding conservative treatment of radial and vertical longitudinal tears.

The three repair techniques detailed in Chapter 3 restored normal contact mechanics to the medial compartment of stifles with a simulated medial meniscal bucket handle tear. Partial meniscectomy caused a 35% decrease in CA, a 57% increase in MCP and a 55% increase in PCP. In contrast, meniscal repair reestablished normal CA, MCP and PCP. The vascular supply to the menisci is restricted to the periphery and the healing potential for a torn meniscus must be considered. Meniscal tears located in the avascular portion of the meniscus are considered avascular and have little potential for healing. Based on our results, consideration should be given to repairing peripheral tears involving the vascular zone of the meniscus if the parenchyma of the meniscus is normal. Partial meniscectomy should be considered for more axial tears and when the torn meniscal tissue is abnormal. Further research is needed to determine the optimal repair technique which should be used in clinically in dogs based on fixation strength and ease of application.

These *ex-vivo* investigations have provided valuable data regarding the contact mechanics of meniscal tears and meniscal repairs. Using digital pressure sensing

system, we were able to accurately estimate the effects of five types of meniscal tears, three types of meniscal repairs, and partial meniscectomy on femerotibial joint contact mechanics. The results of these *ex-vivo* studies should be interpreted with caution. In these studies, the CrCL was left intact. The CrCL was not transected in order to isolate the changes caused by meniscal pathology on contact mechanics. Meniscal pathology rarely occurs isolated from CrCL pathology. The meniscal pathology described in Chapter 2 and the meniscal pathology which was repaired in Chapter 3 was simulated. The simulated tears created in Chapter 2 were made to grossly resemble tears diagnosed in clinical cases but simulation of these tears is an obvious limitation.

The clinical significance of contact mechanic data is disputable. As established in Chapter 2, non-reducible bucket handle, flap and complex meniscal tears cause a statically significant difference in PCP. Although this difference between the PCP of control and tears is of statistical significance, the biologic significance is unknown. Andriacchi postulates that abnormal load distribution will initiate progression of degenerative joint disease.[113] Long-term *in-vivo* studies measuring contact pressures with intra-articular Tekscan sensors have not been performed to support this hypothesis.

Chapters 2 and 3 detail the contact mechanic alterations caused by meniscal tears, meniscal repairs and partial meniscectomy. Although results should be interpreted cautiously, these studies show that non-reducible displaced bucket handle tears, flap tears, and complex tears will cause large alterations in PCP. These findings support the recommendation of debridement of these tears in clinical cases. Radial tears and vertical longitudinal tears do not cause alterations in contact mechanics.

Additional *in-vivo* studies should be performed to determine the optimal treatment for these types of tears. One treatment option that should be considered for vertical longitudinal tears and reducible bucket handle tears located within the vascular zone of the meniscus is meniscal repair. Three types of meniscal repair, horizontal, vertical and cruciate suture repair, were shown to restore normal contact mechanics in Chapter 3. Again, *in-vivo* testing is recommended to determine if meniscal repair should be performed.

LIST OF REFERENCES

1. Sutton JB. Ligaments: their nature and morphology. London: MK Lewis; 1897.

2. Sisson S. The anatomy of the domestic animals. Philadelphia, PA: WB Saunders; 1917.

3. Macconaill MA. The Function of Intra-Articular Fibrocartilages, with Special Reference to the Knee and Inferior Radio-Ulnar Joints. J Anat 1932;66(Pt 2):210-227.

4. King D. The healing of semilunar cartilages. 1936. Clin Orthop Relat Res 1990;(252):4-7.

5. Lipscomb PR, Henderson MS. Internal derangements of the knee. J Am Med Assoc 1947;135(13):827-831.

6. Fairbank TJ. Knee joint changes after meniscectomy. J Bone Joint Surg Am 1948;30B(4):664-670.

7. Allen PR, Denham RA, Swan AV. Late degenerative changes after meniscectomy. Factors affecting the knee after operation. J Bone Joint Surg Br 1984;66(5):666-671.

8. Tapper EM, Hoover NW. Late results after meniscectomy. J Bone Joint Surg Am 1969;51(3):517-526.

9. Appel H. Late results after meniscectomy in the knee joint. A clinical and roentgenologic follow-up investigation. Acta Orthop Scand Suppl 1970;133:1-111.

10. Priddy NH, Tomlinson JL, Dodam JR, Hornbostel JE. Complications with and owner assessment of the outcome of tibial plateau leveling osteotomy for treatment of cranial cruciate ligament rupture in dogs: 193 cases (1997-2001). J Am Vet Med Assoc 2003;222(12):1726-1732.

11. Pacchiana PD, Morris E, Gillings SL, Jessen CR, Lipowitz AJ. Surgical and postoperative complications associated with tibial plateau leveling osteotomy in dogs with cranial cruciate ligament rupture: 397 cases (1998-2001). J Am Vet Med Assoc 2003;222(2):184-193.

12. Kurosawa H, Fukubayashi T, Nakajima H. Load-bearing mode of the knee joint: physical behavior of the knee joint with or without menisci. Clin Orthop Relat Res 1980;(149):283-290.

13. Bullough PG, Munuera L, Murphy J, Weinstein AM. The strength of the menisci of the knee as it relates to their fine structure. J Bone Joint Surg Br 1970;52(3):564-567.

14. Hulse DA. The meniscus: Anatomy, function and treatment. Compend on Contin Educ 2009;5(9):765-775.

15. Allen CR, Wong EK, Livesay GA, Sakane M, Fu FH, Woo SL. Importance of the medial meniscus in the anterior cruciate ligament-deficient knee. J Orthop Res 2000;18(1):109-115.

16. Arnoczky SP, Tarvin GB, Vasseur P. Surgery of the stifle. Part III. The menisci and collateral ligaments. Compendium Contin Educ Pract Vet 1980;11:765-774.

17. Gao J, Oqvist G, Messner K. The attachments of the rabbit medial meniscus. A morphological investigation using image analysis and immunohistochemistry. J Anat 1994;185 (Pt 3):663-667.

18. Gao J, Messner K. Natural healing of anterior and posterior attachments of the rabbit meniscus. Clin Orthop Relat Res 1996;(328):276-284.

19. Arnoczky SP, Warren RF. The microvasculature of the meniscus and its response to injury. An experimental study in the dog. Am J Sports Med 1983;11(3):131-141.

20. Bird MD, Sweet MB. Canals in the semilunar meniscus: brief report. J Bone Joint Surg Br 1988;70(5):839.

21. Zimny ML, Albright DJ, Dabezies E. Mechanoreceptors in the human medial meniscus. Acta Anat (Basel) 1988;133(1):35-40.

22. O'Connor BL. The mechanoreceptor innervation of the posterior attachments of the lateral meniscus of the dog knee joint. J Anat 1984;138 (Pt 1):15-26.

23. Day B, Mackenzie WG, Shim SS, Leung G. The vascular and nerve supply of the human meniscus. Arthroscopy 1985;1(1):58-62.

24. Mine T, Kimura M, Sakka A, Kawai S. Innervation of nociceptors in the menisci of the knee joint: an immunohistochemical study. Arch Orthop Trauma Surg 2000;120(3-4):201-204.

25. Aspden RM, Yarker YE, Hukins DW. Collagen orientations in the meniscus of the knee joint. J Anat 1985;140 (Pt 3):371-380.

26. Fithian DC, Kelly MA, Mow VC. Material properties and structure-function relationships in the menisci. Clin Orthop Relat Res 1990;(252):19-31.

27. Ahmed AM. The load bearing role of the knee menisci. In: Mow VC ASJD, editor. Knee Meniscus: Basic and Clinical Foundations. New York: Raven Press, Ltd.; 1992.

28. Walker PS, Erkman MJ. The role of the menisci in force transmission across the knee. Clin Orthop Relat Res 1975;(109):184-192.

29. Pozzi A, Litsky AS, Field J, Apelt D, Meadows C, Johnson KA. Pressure distributions on the medial tibial plateau after medial meniscal surgery and tibial plateau levelling osteotomy in dogs. Vet Comp Orthop Traumatol 2008;21(1):8-14.

30. Fukubayashi T, Kurosawa H. The contact area and pressure distribution pattern of the knee. A study of normal and osteoarthrotic knee joints. Acta Orthop Scand 1980;51(6):871-879.

31. Ahmed AM, Burke DL. In-vitro measurement of static pressure distribution in synovial joints--Part I: Tibial surface of the knee. J Biomech Eng 1983;105(3):216-225.

32. Krause WR, Pope MH, Johnson RJ, Wilder DG. Mechanical changes in the knee after meniscectomy. J Bone Joint Surg Am 1976;58(5):599-604.

33. Shrive NG, O'Connor JJ, Goodfellow JW. Load-bearing in the knee joint. Clin Orthop Relat Res 1978;(131):279-287.

34. Pozzi A, Kim SE, Lewis DD. Effect of Transection of the Caudal Menisco-Tibial Ligament on Medial Femorotibial Contact Mechanics. Vet Surg. In press.

35. Ghosh P, Taylor TK. The knee joint meniscus. A fibrocartilage of some distinction. Clin Orthop Relat Res 1987;(224):52-63.

36. McCann L, Ingham E, Jin Z, Fisher J. Influence of the meniscus on friction and degradation of cartilage in the natural knee joint. Osteoarthritis Cartilage 2009;17(8):995-1000.

37. King D. The function of semilunar cartilages. J Bone Joint Surg Am 1936;18:1069-1076.

38. Guilak F, Meyer BC, Ratcliffe A, Mow VC. The effects of matrix compression on proteoglycan metabolism in articular cartilage explants. Osteoarthritis Cartilage 1994;2(2):91-101.

39. Radin EL, de LF, Maquet P. Role of the menisci in the distribution of stress in the knee. Clin Orthop Relat Res 1984;(185):290-294.

40. Levy IM, Torzilli PA, Warren RF. The effect of medial meniscectomy on anterior-posterior motion of the knee. J Bone Joint Surg Am 1982;64(6):883-888.

41. Cox JS, Nye CE, Schaefer WW, Woodstein IJ. The degenerative effects of partial and total resection of the medial meniscus in dogs' knees. Clin Orthop Relat Res 1975;(109):178-183.

42. Johnson KA, Francis DJ, Manley PA, Chu Q, Caterson B. Comparison of the effects of caudal pole hemi-meniscectomy and complete medial meniscectomy in the canine stifle joint. Am J Vet Res 2004;65(8):1053-1060.

43. Baratz ME, Fu FH, Mengato R. Meniscal tears: the effect of meniscectomy and of repair on intraarticular contact areas and stress in the human knee. A preliminary report. Am J Sports Med 1986;14(4):270-275.

44. Pena E, Calvo B, Martinez MA, Palanca D, Doblare M. Finite element analysis of the effect of meniscal tears and meniscectomies on human knee biomechanics. Clin Biomech (Bristol , Avon) 2005;20(5):498-507.

45. Pozzi A, Kowaleski MP, Apelt D, Meadows C, Andrews CM, Johnson KA. Effect of medial meniscal release on tibial translation after tibial plateau leveling osteotomy. Vet Surg 2006;35(5):486-494.

46. Papageorgiou CD, Gil JE, Kanamori A, Fenwick JA, Woo SL, Fu FH. The biomechanical interdependence between the anterior cruciate ligament replacement graft and the medial meniscus. Am J Sports Med 2001;29(2):226-231.

47. Lynch MA, Henning CE, Glick KR, Jr. Knee joint surface changes. Long-term follow-up meniscus tear treatment in stable anterior cruciate ligament reconstructions. Clin Orthop Relat Res 1983;(172):148-153.

48. Thieman KM, Tomlinson JL, Fox DB, Cook C, Cook JL. Effect of meniscal release on rate of subsequent meniscal tears and owner-assessed outcome in dogs with cruciate disease treated with tibial plateau leveling osteotomy. Vet Surg 2006;35(8):705-710.

49. Case JB, Hulse D, Kerwin SC, Peycke LE. Meniscal injury following initial cranial cruciate ligament stabilization surgery in 26 dogs (29 stifles). Vet Comp Orthop Traumatol 2008;21(4):365-367.

50. Lafaver S, Miller NA, Stubbs WP, Taylor RA, Boudrieau RJ. Tibial tuberosity advancement for stabilization of the canine cranial cruciate ligament-deficient stifle joint: surgical technique, early results, and complications in 101 dogs. Vet Surg 2007;36(6):573-586.

51. Casale SA, McCarthy RJ. Complications associated with lateral fabellotibial suture surgery for cranial cruciate ligament injury in dogs: 363 cases (1997-2005). J Am Vet Med Assoc 2009;234(2):229-235.

52. Voss K, Damur DM, Guerrero T, Haessig M, Montavon PM. Force plate gait analysis to assess limb function after tibial tuberosity advancement in dogs with

cranial cruciate ligament disease. Vet Comp Orthop Traumatol 2008;21(3):243-249.

53. Ralphs SC, Whitney WO. Arthroscopic evaluation of menisci in dogs with cranial cruciate ligament injuries: 100 cases (1999-2000). J Am Vet Med Assoc 2002;221(11):1601-1604.

54. Smith GN, Mickler EA, Albrecht ME, Myers SL, Brandt KD. Severity of medial meniscus damage in the canine knee after anterior cruciate ligament transection. Osteoarthritis Cartilage 2002;10(4):321-326.

55. Fithian DC, Paxton LW, Goltz DH. Fate of the anterior cruciate ligament-injured knee. Orthop Clin North Am 2002;33(4):621-36, v.

56. Keene GC, Bickerstaff D, Rae PJ, Paterson RS. The natural history of meniscal tears in anterior cruciate ligament insufficiency. Am J Sports Med 1993;21(5):672-679.

57. Bennett D, May C. Meniscal damage assocated with cruciate disease in the dog. J Small Anim Pract 1991;32:111-117.

58. Flo G. Classification of Meniscal Lesions in Twenty-Six Consecutive Canine Meniscectomies. J Am An Hosp Assoc 1983;19:335-340.

59. Hardingham TE, Muir H, Kwan MK, Lai WM, Mow VC. Viscoelastic properties of proteoglycan solutions with varying proportions present as aggregates. J Orthop Res 1987;5(1):36-46.

60. Beaupre A, Choukroun R, Guidouin R et al. [A study of the menisci of the knee by scanning electron microscopy (author's transl)]. Rev Chir Orthop Reparatrice Appar Mot 1981;67(8):713-719.

61. Corr SA, Brown C. A comparison of outcomes following tibial plateau levelling osteotomy and cranial tibial wedge osteotomy procedures. Vet Comp Orthop Traumatol 2007;20(4):312-319.

62. Kim SE, Pozzi A, Banks SA, Conrad BP, Lewis DD. Effect of tibial plateau leveling osteotomy on femorotibial contact mechanics and stifle kinematics. Vet Surg 2009;38(1):23-32.

63. DeYoung DJ, Flo G. Experimental medial meniscectomy in dogs undergoing cranial cruciate ligament repair. J Am An Hosp Assoc 1980;16:639-645.

64. Kim JM, Moon MS. Effect of synovectomy upon regeneration of meniscus in rabbits. Clin Orthop Relat Res 1979;(141):287-294.

65. Arnoczky SP, Warren RF, Kaplan N. Meniscal remodeling following partial meniscectomy--an experimental study in the dog. Arthroscopy 1985;1(4):247-252.

66. Trumble TN, Billinghurst RC, Bendele AM, McIlwraith CW. Evaluation of changes in vertical ground reaction forces as indicators of meniscal damage after transection of the cranial cruciate ligament in dogs. Am J Vet Res 2005;66(1):156-163.

67. Blond L, Thrall DE, Roe SC, Chailleux N, Robertson ID. Diagnostic accuracy of magnetic resonance imaging for meniscal tears in dogs affected with naturally occuring cranial cruciate ligament rupture. Vet Radiol Ultrasound 2008;49(5):425-431.

68. Tivers MS, Mahoney P, Corr SA. Canine stifle positive contrast computed tomography arthrography for assessment of caudal horn meniscal injury: a cadaver study. Vet Surg 2008;37(3):269-277.

69. Samii VF, Dyce J, Pozzi A et al. Computed tomographic arthrography of the stifle for detection of cranial and caudal cruciate ligament and meniscal tears in dogs. Vet Radiol Ultrasound 2009;50(2):144-150.

70. Tivers MS, Mahoney PN, Baines EA, Corr SA. Diagnostic accuracy of positive contrast computed tomography arthrography for the detection of injuries to the medial meniscus in dogs with naturally occurring cranial cruciate ligament insufficiency. J Small Anim Pract 2009;50(7):324-332.

71. Mahn MM, Cook JL, Cook CR, Balke MT. Arthroscopic verification of ultrasonographic diagnosis of meniscal pathology in dogs. Vet Surg 2005;34(4):318-323.

72. Jackson J, Vasseur PB, Griffey S. Pathologic changes in grossly normal menisci in dogs with rupture of the cranial cruciate ligament. J Am Vet Med Assoc 2001;218(8):1281-1284.

73. Adams ME, McDevitt CA, Ho A, Muir H. Isolation and characterization of high-buoyant-density proteoglycans from semilunar menisci. J Bone Joint Surg Am 1986;68(1):55-64.

74. Walker PS, Erkman MJ. The role of the menisci in force transmission across the knee. Clin Orthop Relat Res 1975;(109):184-192.

75. McGinity JB, Geuss LF, Marvin RA. Partial or total meniscectomy: a comparative analysis. J Bone Joint Surg Am 1977;59(6):763-766.

76. Bojrab MJ. Current techniques in small animal surgery. 4th ed ed. Baltimore, Md: Williams & Wilkins; 1998.

77. Flo G, DeYoung DJ. Meniscal injuries and medial meniscectomy in the canine stifle. J Am An Hosp 1978;14:683-689.

78. Flo G. Classification of Meniscal Lesions in Twenty-Six Consecutive Canine Meniscectomies. J Am An Hosp Assoc 1983;19:335-340.

79. Tibiofemoral contact mechanics and medial meniscal strain after serial meniscectomies in the dog stifle. Veterinary Orthopedic Society Conference; 09 Feb; 2009.

80. Englund M, Roos EM, Roos HP, Lohmander LS. Patient-relevant outcomes fourteen years after meniscectomy: influence of type of meniscal tear and size of resection. Rheumatology (Oxford) 2001;40(6):631-639.

81. Englund M, Lohmander LS. Risk factors for symptomatic knee osteoarthritis fifteen to twenty-two years after meniscectomy. Arthritis Rheum 2004;50(9):2811-2819.

82. Slocum B, Slocum TD. Tibial plateau leveling osteotomy for cranial cruciate ligament. In: Bojrab MJ, editor. Current Techniques in Small Animal Surgery. 4 ed. Baltimore: Williams and Wilkins; 1998:1197-1199.

83. Slocum B, Slocum TD. Tibial plateau leveling osteotomy for cranial cruciate ligament. In: Bojrab MJ, editor. Current Techniques in Small Animal Surgery. 4 ed. Baltimore: Williams and Wilkins; 1998:1197-1199.

84. Kennedy SC, Dunning D, Bischoff MG, Kuriashkin IV, Pijanowski GJ, Schaeffer DJ. The effect of axial and abaxial release on meniscal displacement in the dog. Vet Comp Orthop Traumatol 2005;18(4):227-234.

85. Pozzi A, Litsky AS, Field J, Apelt D, Meadows C, Johnson KA. Pressure distributions on the medial tibial plateau after medial meniscal surgery and tibial plateau levelling osteotomy in dogs. Vet Comp Orthop Traumatol 2008;21(1):8-14.

86. Luther JK, Cook CR, Cook JL. Meniscal release in cruciate ligament intact stifles causes lameness and medial compartment cartilage pathology in dogs 12 weeks postoperatively. Vet Surg 2009;38(4):520-529.

87. Managing the Medial Meniscus-2. American College Veterinary Surgery Symposium; 5 A.D. Oct 20; 2005.

88. Meniscal Repair and Regeneration. American College Veterinary Surgery Symposium; 7 A.D. Oct 20; 2007.

89. Moses PA. A technique for the surgical repair of caudal peripheral detachment and longitudinal peripheral tears of the medial meniscus in dogs. Vet Comp Orthop Traumatol 2002;15:92-96.

90. Kawai Y, Fukubayashi T, Nishino J. Meniscal suture. An experimental study in the dog. Clin Orthop Relat Res 1989;(243):286-293.

91. Cabaud HE, Rodkey WG, Fitzwater JE. Medical meniscus repairs. An experimental and morphologic study. Am J Sports Med 1981;9(3):129-134.

92. Newman AP, Anderson DR, Daniels AU, Dales MC. Mechanics of the healed meniscus in a canine model. Am J Sports Med 1989;17(2):164-175.

93. Koukoubis TD, Glisson RR, Feagin JA, Jr. et al. Meniscal fixation with an absorbable staple. An experimental study in dogs. Knee Surg Sports Traumatol Arthrosc 1997;5(1):22-30.

94. Nishida M, Higuchi H, Kobayashi Y, Takagishi K. Histological and biochemical changes of experimental meniscus tear in the dog knee. J Orthop Sci 2005;10(4):406-413.

95. Venkatachalam S, Godsiff SP, Harding ML. Review of the clinical results of arthroscopic meniscal repair. Knee 2001;8(2):129-133.

96. Jackson J, Vasseur PB, Griffey S. Pathologic changes in grossly normal menisci in dogs with rupture of the cranial cruciate ligament. J Am Vet Med Assoc 2001;218(8):1281-1284.

97. A comparison of contact mechanics of three meniscal repair techniques and partial meniscectomy in cadaveric dog stifles. Veterinary Orthopedic Society Conference; 2009.

98. Dienst M, Kohn D. [Allogenic meniscus transplantation]. Oper Orthop Traumatol 2006;18(5-6):463-480.

99. Cook JL, Fox DB, Malaviya P et al. Evaluation of small intestinal submucosa grafts for meniscal regeneration in a clinically relevant posterior meniscectomy model in dogs. J Knee Surg 2006;19(3):159-167.

100. Cook JL, Tomlinson JL, Kreeger JM, Cook CR. Induction of meniscal regeneration in dogs using a novel biomaterial. Am J Sports Med 1999;27(5):658-665.

101. Tienen TG, Heijkants RG, de Groot JH et al. Replacement of the knee meniscus by a porous polymer implant: a study in dogs. Am J Sports Med 2006;34(1):64-71.

102. Tienen TG, Heijkants RG, de Groot JH et al. Meniscal replacement in dogs. Tissue regeneration in two different materials with similar properties. J Biomed Mater Res B Appl Biomater 2006;76(2):389-396.

103. Tienen TG, Heijkants RG, Buma P, de Groot JH, Pennings AJ, Veth RP. A porous polymer scaffold for meniscal lesion repair--a study in dogs. Biomaterials 2003;24(14):2541-2548.

104. de Groot JH, de VR, Pennings AJ, Klompmaker J, Veth RP, Jansen HW. Use of porous polyurethanes for meniscal reconstruction and meniscal prostheses. Biomaterials 1996;17(2):163-173.

105. Arnoczky SP, Warren RF, Spivak JM. Meniscal repair using an exogenous fibrin clot. An experimental study in dogs. J Bone Joint Surg Am 1988;70(8):1209-1217.

106. Steadman JR, Rodkey WG. Tissue-engineered collagen meniscus implants: 5- to 6-year feasibility study results. Arthroscopy 2005;21(5):515-525.

107. Linke RD, Ulmer M, Imhoff AB. [Replacement of the meniscus with a collagen implant (CMI)]. Oper Orthop Traumatol 2006;18(5-6):453-462.

108. Stollsteimer GT, Shelton WR, Dukes A, Bomboy AL. Meniscal allograft transplantation: a 1- to 5-year follow-up of 22 patients. Arthroscopy 2000;16(4):343-347.

109. Tashman S, Anderst W, Kolowich P, Havstad S, Arnoczky S. Kinematics of the ACL-deficient canine knee during gait: serial changes over two years. J Orthop Res 2004;22(5):931-941.

110. Papageorgiou CD, Gil JE, Kanamori A, Fenwick JA, Woo SL, Fu FH. The biomechanical interdependence between the anterior cruciate ligament replacement graft and the medial meniscus. Am J Sports Med 2001;29(2):226-231.

111. Korvick DL, Pijanowski GJ, Schaeffer DJ. Three-dimensional kinematics of the intact and cranial cruciate ligament-deficient stifle of dogs. J Biomech 1994;27(1):77-87.

112. Whitney WO. Arthroscopically assisted surgery of the stifle joint. In: Beale B, Hulse DA, Schulz KS, Whitney WO, editors. Small animal arthroscopy. Philadelphia, Pa: Saunders; 2003:137-140.

113. Andriacchi TP, Mundermann A, Smith RL, Alexander EJ, Dyrby CO, Koo S. A framework for the in vivo pathomechanics of osteoarthritis at the knee. Ann Biomed Eng 2004;32(3):447-457.

114. Jones RS, Keene GC, Learmonth DJ et al. Direct measurement of hoop strains in the intact and torn human medial meniscus. Clin Biomech (Bristol , Avon) 1996;11(5):295-300.

115. Arnoczky SP, Warren RF. The microvasculature of the meniscus and its response to injury. An experimental study in the dog. Am J Sports Med 1983;11(3):131-141.

116. Wirz D, Becker R, Li SF, Friederich NF, Muller W. [Validation of the Tekscan system for statistic and dynamic pressure measurements of the human femorotibial joint]. Biomed Tech (Berl) 2002;47(7-8):195-201.

117. Hottinger HA, DeCamp CE, Olivier NB, Hauptman JG, Soutas-Little RW. Noninvasive kinematic analysis of the walk in healthy large-breed dogs. Am J Vet Res 1996;57(3):381-388.

118. Voss K, Imhof J, Kaestner S, Montavon PM. Force plate gait analysis at the walk and trot in dogs with low-grade hindlimb lameness. Vet Comp Orthop Traumatol 2007;20(4):299-304.

119. Lee SJ, Aadalen KJ, Malaviya P et al. Tibiofemoral contact mechanics after serial medial meniscectomies in the human cadaveric knee. Am J Sports Med 2006;34(8):1334-1344.

120. Changes in joint congruency following medial meniscus tear and repair. 54th Annual Meeting of the Orthopedic Research Society; San Francisco: 2008.

121. Weiss CB, Lundberg M, Hamberg P, DeHaven KE, Gillquist J. Non-operative treatment of meniscal tears. J Bone Joint Surg Am 1989;71(6):811-822.

122. Cao M, Stefanovic-Racic M, Georgescu HI, Miller LA, Evans CH. Generation of nitric oxide by lapine meniscal cells and its effect on matrix metabolism: stimulation of collagen production by arginine. J Orthop Res 1998;16(1):104-111.

123. LeGrand A, Fermor B, Fink C et al. Interleukin-1, tumor necrosis factor alpha, and interleukin-17 synergistically up-regulate nitric oxide and prostaglandin E2 production in explants of human osteoarthritic knee menisci. Arthritis Rheum 2001;44(9):2078-2083.

124. Tandogan RN, Taser O, Kayaalp A et al. Analysis of meniscal and chondral lesions accompanying anterior cruciate ligament tears: relationship with age, time from injury, and level of sport. Knee Surg Sports Traumatol Arthrosc 2004;12(4):262-270.

125. Cox JS, Cordell LD. The degenerative effects of medial meniscus tears in dogs' knees. Clin Orthop Relat Res 1977;(125):236-242.

126. Ridge PA. Isolated medial meniscal tear in a Border Collie. Vet Comp Orthop Traumatol 2006;19(2):110-112.

127. Kim SE, Pozzi A, Banks SA, Conrad BP, Lewis DD. Effect of tibial tuberosity advancement on femorotibial contact mechanics and stifle kinematics. Vet Surg 2009;38(1):33-39.

128. Harris ML, Morberg P, Bruce WJ, Walsh WR. An improved method for measuring tibiofemoral contact areas in total knee arthroplasty: a comparison of K-scan sensor and Fuji film. J Biomech 1999;32(9):951-958.

129. Bristow WR. Internal Derangement of the Knee Joint. J Bone Joint Surg Am 1935;17:605-626.

130. Wyland DJ, Guilak F, Elliott DM, Setton LA, Vail TP. Chondropathy after meniscal tear or partial meniscectomy in a canine model. J Orthop Res 2002;20(5):996-1002.

131. Hulse D, Shires PK. Observation of the posteromedial compartment of the stifle joint. J Am An Hosp 1981;17:575-578.

132. Logan M, Watts M, Owen J, Myers P. Meniscal repair in the elite athlete: results of 45 repairs with a minimum 5-year follow-up. Am J Sports Med 2009;37(6):1131-1134.

133. Muellner T, Egkher A, Nikolic A, Funovics M, Metz V. Open meniscal repair: clinical and magnetic resonance imaging findings after twelve years. Am J Sports Med 1999;27(1):16-20.

134. Dowdy PA, Miniaci A, Arnoczky SP, Fowler PJ, Boughner DR. The effect of cast immobilization on meniscal healing. An experimental study in the dog. Am J Sports Med 1995;23(6):721-728.

135. Cabaud HE, Rodkey WG, Fitzwater JE. Medical meniscus repairs. An experimental and morphologic study. Am J Sports Med 1981;9(3):129-134.

136. Newman AP, Anderson DR, Daniels AU, Dales MC. Mechanics of the healed meniscus in a canine model. Am J Sports Med 1989;17(2):164-175.

137. Chow JCY. Advanced arthroscopy. New York: Springer; 2001.

138. Barber FA, McGarry JE. Meniscal repair techniques. Sports Med Arthrosc 2007;15(4):199-207.

139. Thieman KM, Pozzi A, Ling HY, Lewis DD, Horodyski M. Contact mechanics of simulated meniscal tears in cadaveric canine stifles. 2009;38(7):803-810.

140. Thieman KM, Pozzi A, Ling H, Lewis DD, Horodysky MB. The contact mechanics of simulated meniscal tears in cadaveric dog stifles. Vet Surg. In press.

141. Becker R, Wirz D, Wolf C, Gopfert B, Nebelung W, Friederich N. Measurement of meniscofemoral contact pressure after repair of bucket-handle tears with biodegradable implants. Arch Orthop Trauma Surg 2005;125(4):254-260.

142. Optical coherence tomography for diagnosing meniscal pathology in dogs: A pilot study. Veterinary Orthopedic Society Conference; 09 Feb 27; 2009.

143. Tayton E, Verma R, Higgins B, Gosal H. A correlation of time with meniscal tears in anterior cruciate ligament deficiency: stratifying the risk of surgical delay. Knee Surg Sports Traumatol Arthrosc 2009;17(1):30-34.

144. Meakin JR, Shrive NG, Frank CB, Hart DA. Finite element analysis of the meniscus: the influence of geometry and material properties on its behaviour. Knee 2003;10(1):33-41.

145. Asik M, Sener N, Akpinar S, Durmaz H, Goksan A. Strength of different meniscus suturing techniques. Knee Surg Sports Traumatol Arthrosc 1997;5(2):80-83.

146. Kohn D, Siebert W. Meniscus suture techniques: a comparative biomechanical cadaver study. Arthroscopy 1989;5(4):324-327.

147. Kocabey Y, Chang HC, Brand JC, Jr., Nawab A, Nyland J, Caborn DN. A biomechanical comparison of the FasT-Fix meniscal repair suture system and the RapidLoc device in cadaver meniscus. Arthroscopy 2006;22(4):406-413.

148. Abdelkafy A, Wlk M, Krasny C, Landsiedl F. The "cruciate suture" for arthroscopic meniscal repair: a new technique. Arthroscopy 2006;22(10):1134-1135.

149. Siebold R, Dehler C, Boes L, Ellermann A. Arthroscopic all-inside repair using the Meniscus Arrow: long-term clinical follow-up of 113 patients. Arthroscopy 2007;23(4):394-399.

BIOGRAPHICAL SKETCH

Kelley Thieman graduated from the University of Missouri in 2002 with a Bachelor of Science degree in biology. After graduation, she attended the veterinary medical school at the University of Missouri and graduated with the degree of Doctor of Veterinary Medicine in 2006. After graduation, she completed a one year rotating small animal internship at the University of Tennessee. In 2007, Kelley began a small animal surgical residency and work toward a master's degree at the University of Florida. She is scheduled to complete her residency training in 2011.