MEASURING BONE DENSITY AT DISTANCES LATERAL TO THE BONE-IMPLANT INTERFACE WITH VARIOUS STAGES OF LOADING: A HISTOMORPHOMETRIC ANALYSIS IN THE BABOON

By

LARA L. TULL

A THESIS PRESENTED TO THE GRADUATE SCHOOL
OF THE UNIVERSITY OF FLORIDA IN PARTIAL FULFILLMENT
OF THE REQUIREMENTS FOR THE DEGREE OF
MASTER OF SCIENCE

UNIVERSITY OF FLORIDA

2003

ACKNOWLEDGMENTS

To my husband, Greg, I thank him for all of his support, friendship, inspiration, patience, and sacrifices throughout our journey as residents. I look forward to our future together and all it will bring.

To my daughter Hope, she alone is worth all the hard work and effort.

To my family, I thank them for guiding and supporting me throughout my many years of school and training.

I owe a special thanks to Dr. Vernino for all his contributions to my research project. I am very honored to have been able to work with him. I would also like to thank the members of my committee—Drs. Towle, Brown, and Vernino. I would also like to thank Dr. Gray and Sal Renato for their initial help with my project. I give a special thanks to my director, Dr. Horning, for his wonderful input and advice. Many thanks go to Sean Kohles for his assistance with the statistical analysis.

TABLE OF CONTENTS

Abstract of Thesis Presented to the Graduate School
of the University of Florida in Partial Fulfillment of the
Requirements for the Degree of Master of Science

MEASURING BONE DENSITY AT DISTANCES LATERAL TO THE
BONE-IMPLANT INTERFACE WITH VARIOUS STAGES OF LOADING:
A HISTOMORPHOMETRIC ANALYSIS IN THE BABOON

By

Lara L. Tull

December 2003

Chair: Herbert J. Towle, III
Major Department: Periodontics

The quality of bone or bone density adjacent to a dental implant is an important consideration when evaluating the success of dental implants. The purpose of this study was to measure histomorphometrically, the percent of bone along the perimeter of dental implants at distances of 0.5mm and 1.0 mm from the bone-implant interface as compared to the implant-bone interface; and to determine if there were differences between percentage of bone between early loaded versus unloaded implants with time.

The research protocol was reviewed and approved by the Institutional Animal Care and Use Committee of the University of Oklahoma Health Sciences Center. There were a total of 120 dental implants placed in ten female baboons of poor quality bone. The experimental sites received Osseotite™ surface implants with size of 3.75mm diameter x 10 mm in length. Unloaded control implants with one-half Osseotite™ and one-half commercialy pure titanium (cpTi) surfaces were also placed. Block sections were

obtained and prepared as plastic embedded undecalcified sections. Photomicrographs and histomorphometric analysis were completed. The proportion of bone contact was calculated from the summation of linear osseous contact along the buccal and lingual sides divided by the total available implant perimeter in the selected region at distances of 0.5mm and 1.0mm adjacent to the implant-bone interface. A template was used to superimpose the implant profile on the peri-implant bone.

The unloaded controls had mean bone densities of 62.5% at 0.0mm, 45.2% at 0.5mm, and 44.1% at 1.0mm. The 1, 2, and 4 month unloaded implant groups had higher percentages of osseous tissue at lateral distances compared to the 5 month unloaded group. The loaded test group of 1-month healing plus 3 months of occlusal loading exhibited mean bone densities of 76.6% at 0.0mm, 59.2% at 0.5mm, and 55.5% at 1.0mm.The loaded test group of 2 months of healing plus 3 months of occlusal loading expressed mean bone densities of 77.2% at 0.0mm, 61.0% at 0.5mm,and 57.1% at 1.0mm.

There was a lateral increase of bone densities in the occlusally loaded test groups, which correlate to appositional bone response in the peri-implant and bone-implant areas. The increase in bone densities can be interpreted as functional adaptation or Wolff's Law.

The statistically significant decrease in bone densities at the 5 month unloaded group suggests there is a critical time period when dental implants should be placed into occlusal function. Therefore, a dental implant that remains dormant for too long may be at risk for a decrease in bone density. This could be due to disuse atrophy from a lack of functional stimulation.

CHAPTER 1
INTRODUCTION

The quality of bone or density of bone adjacent to dental implants is an important consideration in the success of dental implants. There are four established bone qualities in the oral cavity as described by Lekholm and Zarb.[1] Quality 1 consists of primarily dense cortical bone that is usually located in the anterior mandible. Quality 2 has a thick layer of compact bone that surrounds a core of dense trabecular bone that is usually associated with the posterior mandible. Quality 3 has a thin layer of cortical bone that surrounds a core of dense trabecular bone, which is usually associated with the anterior maxilla. Quality 4 has a thin layer of cortical bone that surrounds a core of lower density trabecular bone. The posterior maxilla is customarily composed of this least dense quality of bone. This classification system has been used to characterize bone quality during surgical procedures for implant placement. Since this classification can be subjective, other investigators have proposed an extension of this idea by comparing the surgical resistance of the bone during osteotomy preparation.[2-6] However, a study by Misch states that bone quality 1 and 4 can easily be differentiated, but quality 2 and 3 are not as easily discerned.[6]

Actual bone density adjacent to the dental implant may provide valuable predictive information regarding implant performance. One method for determining bone density adjacent to dental implants includes histomorphometric analyses of bone biopsies. Several studies have histomorphometrically evaluated the bone-to-implant contact (BIC)

at the implant-bone interface.[7-15] Bone-to-implant contact is a histologic concept traditionally assessed by calculating the amount of the implant surface directly attached to mineralized bone without the interposition of soft connective tissue. Studies have shown that titanium implant surfaces usually require a high percentage of bone contact for successful long-term stability.[7, 11, 12, 16, 17] The percentage of bone contact also depends on implant surface characteristics, local bone density, healing time, and loading time.[9-10,15-21]

Abbreviated implant healing times followed by early occlusal loading have been evaluated and proven to be clinically efficacious.[20-28] In a study by Vernino et al., loading dental implants in baboons after 1 and 2 months of healing showed no clinical or histological statistical differences in mean BIC.[10] The overall mean BIC for the 1-month healing group was 76.6% ± 14.4% and the 2-month healing group was 77.2% ± 12.2%. These results are slightly greater than the findings of Piattelli et al.[19] Using Rhesus monkeys, they reported bone contact of 51.9% on machine-surface implants after 1 month of healing. Another study by Piatelli et al. evaluated titanium plasma-sprayed implants restored after 2 weeks of healing and 8 months of loading in the monkey. There were comparable bone contact values of 67.2% in the maxilla and 80.7% in the mandible.[26]

Osseous support for the dental implant may be influenced by the bone density at various distances from the implant to bone interface. There are limited reports regarding the peri-implant bone reaction and occlusal load. In a study by Isisdor, using a non-human primate model, it was demonstrated that excessive occlusal load in a lateral direction caused implant failure and fractures in the peri-implant bone.[29] As reported by

Trisi, actual bone-implant-contact and expected bone-implant-contact were laterally measured at 0.15, 0.5, and 1.0mm with 6 months of healing. They showed that with a rougher surface, there was more bone-implant contact versus laterally expected-bone-implant contact.[7] Other studies indicate that there is no bone loss or resorption induced by occlusal load, orthodontic load, or prosthesis misfit.[30-36] On the other hand, in a report by Gotfredsen, laterally loaded test implants exhibited a higher bone density and more mineralization compared to unloaded controls.[37]

The bone reaction that occurs laterally to the bone-implant interface may be explained by the physiologic phenomena of Frost's and Wolff's Laws. The reaction of bone to mechanical loading has been reviewed by Frost.[38] He described bone deformation below a certain threshold would be repaired by remodeling. If bone deformation exceeds a certain threshold, the repair mechanism could result in irreversible bone damage. Another explanation of physiologic bone reaction is Wolff's Law. It states that bone tends to develop the structure best suited to resist the prevailing forces acting upon it, a phenomenon known as "functional adaption."[39] In other words, once bone is placed in function, it becomes more dense with time. The dental literature is lacking support for the phenomenon of Wolff's Law occurring around dental implants.

There are questions that still remain regarding the influence of bone density of the peri-implant bone with early occlusal load. The purpose of this study was to measure histomorphometrically the percent of bone density that is lateral to the perimeter of dental implants at distances of 0.5 and 1.0mm adjacent to the bone-implant interface at various loading sequences. Additionally, comparisons were made to determine if there were differences between the percent density of bone between early loaded versus unloaded implants with time; and to compare the actual bone-implant contact densities

with the peri-implant bone-implant densities. An established baboon model as devised by Vernino et al. was selected to demonstrate this comparison and provide further clinically relevant information for long-term implant function.[10]

CHAPTER 2
MATERIALS AND METHODS

This study is part of an ongoing study that was approved by the Institutional Animal Care and Use Committee of the University of Oklahoma Health Science Center. All surgical and histological procedures were carried out at the University of Oklahoma prior to beginning this study. There were 120 dental implants placed in a randomized longitudinal block design in ten adult female baboons (Papio anubis) in this investigation according to study protocol as reported by Vernino et al.[10] The animals ranged from 10 to 16 years of age and weighed between 15 and 17 kilograms each. The previous medical and research history of the animals were reviewed to exclude other research usage and/or systemic therapy within the prior year. All research animals were housed at the primate animal facility and were transported to the primate operating area for all surgical procedures.

Surgical Phase

The animals were sedated and placed under general anesthesia for all surgical procedures. The sedations were administered with ketamine hydrochloride (10mg/kg) and xylazine HCl (2mg) injected intramuscularly. Isofluorane at 0.7% to 1.5% gaseous concentration was delivered via endotracheal tube. Local anesthesia was used to control pain and excessive hemorrhage. The maxillary and mandibular premolars and 1st molars were removed and the edentulous ridge was reduced 3 to 4 mm in height to provide a more suitable ridge for implant placement. At 3 months following the healing of

extraction sockets, the initial incisions were made midcrestally and mucoperiosteal flaps were elevated for access to the underlying bony ridge.

Study Protocol

There were a 120 total dental implants placed in the 10 animals, with 12 implants placed in each animal (6 in the maxilla and 6 in the mandible). The experimental sites received Osseotite™ surface implants of 3.75mm in diameter and 10 mm in length. At the unloaded control, implants with one-half of the surface Osseotite™ and the other half, commercially pure titanium (CpTi) surfaces were placed. Following placement of all implants, radiographs, and photographs were obtained.

Impressions were made with the transfer copings in place for fabrication of the indicated restorations after the designated healing periods had elapsed in those implants with subsequent loading. The mucoperiosteal flaps were coapted to ensure coverage of the implants and sutured with 4-0 silk or 4-0 gut suture. The animals were examined on a weekly basis for debridement of the surgical sites using sponge toothettes with Peridex, and then photographed. The sutures were removed at 2 weeks post surgery. Implant loading and removal of the block sections then followed study protocol to assure the temporal parameters of the study.

The test groups consisted of 80 Osseotite™ 3.75mm X 10mm implants that were placed and allowed to heal for one month (n=40) or for 2 months (n=40), and then functionally loaded with single crowns for a period of 3 months. Test group A consisted of 40 implants with healing of one month and subsequent load for 3 month period. The implants of group A had a total time of 4 months of healing before harvesting. Test group B consisted of 40 implants that were allowed to heal for 2 months and then were

functionally loaded with crowns for 3 months. This group had 5 months of healing before en bloc harvest. The fixed restorations were monitored and adjusted occlusally as needed during the study. After 3 months of occlusal loading in both test groups, block sections of the implants and surrounding tissues were removed and radiographed. All harvested specimens were prepared for nondecalcified sectioning and histologic processing as described by Donath.[40] The specimens were submitted and prepared at the University of Oklahoma College of Dentistry Department of Oral Pathology.

The 40 control CpTi/Osseotite™ implants were designed to compare the differences between machined and Osseotite™ surface for actual bone densities. For the purpose of this study, the differences between the two surfaces were not measured because it was found in Vernino et al, that there was no difference detected among the Osseotite™ surface and the machined surfaces according to the original study. The implants were left unloaded for1 month (n=10), 2 months (n=10), 4 months (n=10), or 5 months (n=10). (Table 1) After the designated healing times, the implants were removed via block sections to include surrounding tissues. All specimens were prepared for non-decalcified sectioning and histologic evaluation.

Table 1. Study design

Loading sequence	Implants (n)	Test or control
1 month of no loading	10	Control
2 months of no loading	10	Control
4 months of no loading	10	Control
5 months of no loading	10	Control
1 month healing + 3 month of loading	40	Test
2 months healing + 3 months of loading	40	Test

Histological Processing and Image Analysis

The block sections were fixed in 10% formalin for 5 days and prepared for nondecalcified sectioning according to Donath.[40] Specimens were fixed, dehydrated, and

embedded in methyl methacrylate, then sectioned buccolingually along the longitudinal axis of each implant to visualize the implant and adjacent bone. Sections were ground to a thickness of 10 to 15μm and stained with 1% toluidine blue in a 4:1 solution (1% borax/1% pyronin G). The prepared sections were examined and photographed with a 35-mm Wild Photoautomat MPS55 camera mounted on an Olympus model BHA microscope. The resulting film magnification during analysis was 10X given a 2X fluoride lens and a 5X photographic eyepiece. The color slides were digitized (Nikon Cool Scan LS-1000), and converted to computerized JPEG files (Figure 1).

Figure 1. Digitized histologic appearance of implant after 2 months of healing and 3 months of occlusal loading (toluidine blue stain; original maginification x 10).

Histomorphometric Measurements

The digitized photomicrographs were analyzed and recorded using a computer software program (NIH Image Systems™, Image J software; Excel, Microsoft, Redmond, WA). Then osseous contact measurements were then completed at 0.5mm and 1.0mm lateral to the implant-bone interface. Measurements extended from the first thread to the last corresponding thread for each of the 120 implants placed (Figure 2). The proportion of bone contact was calculated from the summation of actual linear

osseous contact along the buccal and lingual sides divided by the total available perimeter in the selected region at distances of 0.5mm and 1.0mm lateral to the implant perimeter. A template was used to superimpose the implant profile on peri-implant bone and measurements were recorded of osseous tissue contact along the profile area at 0.5 and 1.0 mm lateral to the implant profile. The contact points were given a qualitative value of either osseous tissue, marrow, dentin/cementum, PDL, gingival/connective tissue, or not readable.

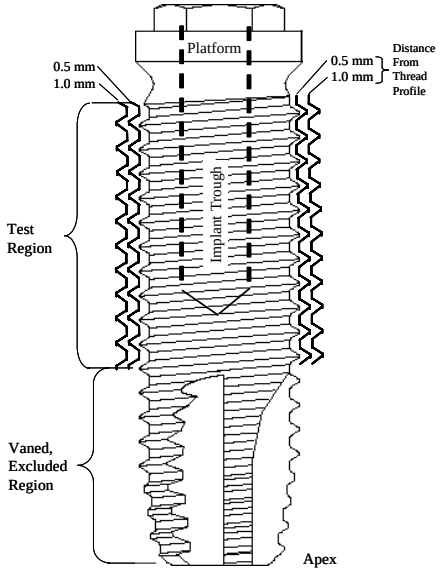

Figure 2. Implant schematic depicting the test regions lateral to the implant-interface and the areas of contact measurements for bone density.

All measurements were determined histomorphometrically and expressed as percentages of osseous tissue contact at the designated perimeter of each implant. The evaluation of the hypothesized equivalence between treatment groups was done using the middle region (the test region) located immediately below the machined surface area and immediately above the vaned region. All reported results of osseous contact analysis in this study reflect values within this test region (Figure 2). The reasons for excluding the several distinct geometric elements of the implant was their potential to effect on the

recording and interpretation of data. For example, the implant's coronal aspect included a machined-surface region extending above the threads to the shoulder. The apex region of the implant had a cutting-edge design with inclusions or vanes that are likely to partially cut during sectioning. The coronal and apical regions were neither representative of the Osseotite™ acid-etched surface nor provided a uniform surface to measure tissue apposition.

Statistical Analysis

Commercially available software was used for all analyses (NIH Imageä™, Bethesda, MD; Excel, Microsoft, Redmond, WA; and Statview v5.0.1, SAS Institute, Inc., Cary, NC). Statistical significance was selected at $p<0.05$. The dependent variable in all analyses was the percent osseous contact along the implant surface profile directly appositional or along profiles drawn at 0.5 and 1.0 mm distant from the implant surface. The influence of such independent variables included animal, test group, tooth site, anatomic site/quadrant, implant surface type, loading time, unloaded/healing time, implant side, and surface profile distance. For ANOVA tables with multiple covariates and factors, the p-value associated with each individual factor describes its statistical influence while accounting for the remaining factors. Interactive influences were subsequently characterized. Some of the multivariate analysis combinations and a repeated measure ANOVA were not possible due to incomplete comparison groups. Where appropriate, Fischer's Protected Least Significant Difference (PLSD), a robust post-hoc analysis, was completed. Percentages of osseous tissue are reported as means and standard deviations.

CHAPTER 3
RESULTS

The percentages of osseous tissue were measured lateral to the perimeter of the implant at distances of 0.5 and 1.0 mm adjacent to the bone-implant-interface at various loading sequences. The results of the original study by Vernino et al were combined with the data of this investigation at the bone-implant interface, or a distance of 0.0mm from the implant profile.[10] Also, the osseous contact percentages for the control unloaded implants with one-half Osseotite™ and one-half CpTi were compiled collectively, since it was found that there was no difference in percentages of bone contact at the implant-interface between the two surfaces topographies in the original study. Therefore, it was not necessary to separate the machined from dual acid-etched implant surfaces which had no bearing on the data obtained from the unloaded implants at lateral distances. The unloaded controls ranged from mean bone densities of 29.5% to 54.2 % for 1, 2, 4, and 5 months of healing. The loaded test implants ranged from mean bone densities of 57.1% to 61% for 1 month of healing plus 3 months of loading and 2 months of healing plus 3 months of loading respectively. The mean bone densities for the 1 month healing plus 3 months of loading at 0.5mm was 59.2% ± 20.2% and 55.5% ± 23.6% at 1.0mm. The 2 month healing plus 3 months of loading group had mean bone densities of 61.0% ± 19.7% at 0.5mm and 57.1% ± 21.6% at 1.0mm (Table 2).

The percentage of bone density is influenced by the lateral distances from the implant at 0.5 and 1.0mm ($p < 0.0001$) when comparing to 0.0mm (Table 3). Regression

analysis revealed as the distance from the implant surface increases, the bone density decreases (Figure 3).

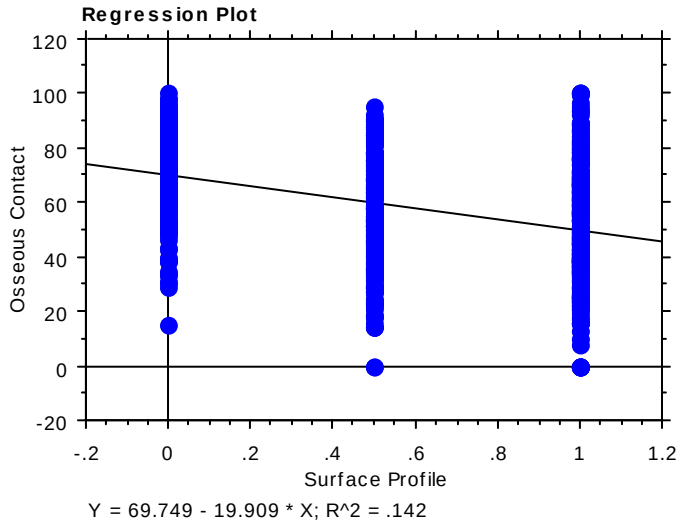

Figure 3. Regression plot diagram of percentages osseous contact with lateral surface profile distances of 0.0, 0.5, and 1.0mm.

Table 2. Summary of osseous tissue percentages with early and no loading at distances adjacent to the implant interface

Loading Sequence	Mean % ± standard deviation at 0.0mm	Mean % ± standard deviation at 0.5mm	Mean % ± standard deviation at 1.0mm
1 month no load	50.9 ± 10.2	49.1 ± 15.2	50.2 ± 18.8
2 month no load	62.3 ± 15.9	44.6 ± 13.0	43.5 ± 19.5
4 month no load	75.6 ± 13.3	54.2 ± 22.3	53.1 ± 22.3
5 month no load	61.1 ± 15.0	32.8 ± 11.0	29.5 ± 10.2
1 month healing + 3 months load	76.6 ± 14.4	59.2 ± 20.2	55.5 ± 23.6
2 month healing + 3 months load	77.2 ± 12.2	61.0 ± 19.7	57.1 ±21.6

The determination of whether there is a difference between percentages of density of bone between early loaded versus unloaded implants was found to be statistically significant ($p < 0.0001$). Loading time does influence the effect of percentages of bone density in a manner in which bone density increases with the amount of time the implant is loaded (Table 3).

Table 3. ANOVA table for osseous contact

Variables	P-Value
Distances of 0.0, 0.5mm, and 1.0mm	<0.0001
Load sequences	<0.0001
Distances and load sequences	0.0191

When the relationship between lateral distances of 0.0, 0.5, and 1.0mm were combined with the effect of early loaded and unloaded implants on bone density, there was statistical significance of p = 0.0191 (Table 3). The bone density was higher in occlusally loaded implants at distances of 0.0, 0.5 and 1.0mm than unloaded implants with time. When comparing the bone densities at 1 month no load, 4 month no load, and 1 month healing plus 3 months of occlusally loading groups, the percentages of osseous tissue increased at lateral distances with the passage of time for the set distances (Figure 4). The one-month group had bone mean bone densities of 50.9%, 49.1%, and 50.2% at 0.0, 0.5, and 1.0mm respectively. The 4-month no load group had mean bone densities of 75.6%, 54.2%, and 53.1% at 0.0, 0.5, and 1.0mm respectively. When comparing those two groups to the 1-month plus 3 months of loading group, there was 76.6%, 59.2%, 55.5% bone densities at 0.0, 0.5, and 1.0mm respectively, resulting in higher bone densities with the occlusally loaded group.

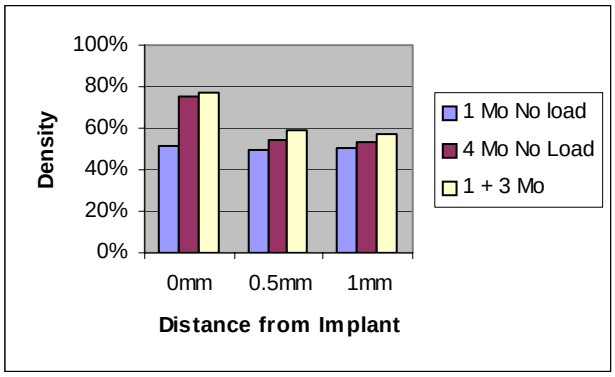

Figure 4. Bone density with time, loading, and distance from implant for the groups of 1 month no load, 4 months no load, and 1 month healing plus 3 months of occlusal load.

When comparing the 2-month no load, 5 month no load, and the 2 month healing plus 3 months of occlusal loading groups, the bone densities also increased with time of load (Figure5). The 5-month no load group had statistically significant less bone density than the 2-month no load group at distances of 0.5 and 1.0mm with a p-value <0.0001(Table 4) There was a statistical difference between the 2 month of healing plus 3 month of loading group and the 5 month no load group at p-value of < 0.0001 (Table 4).

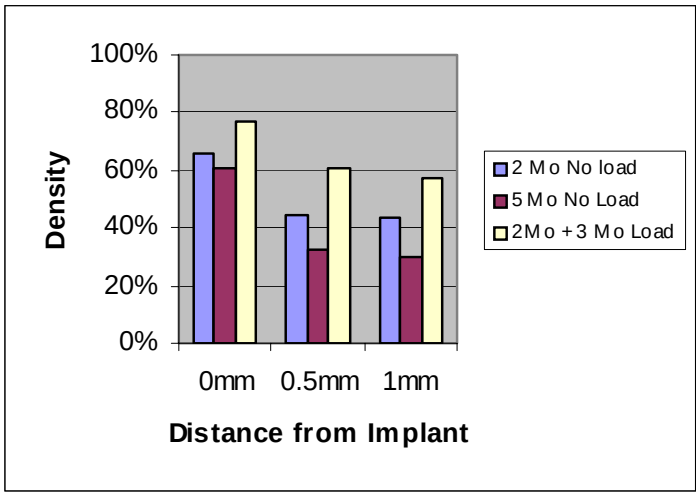

Figure 5. Bone density with time, loading, and distance from implant for the groups of 2 months no load, 5 month no load, and 2 months of healing plus 3 months of occlusal load.

Table 4. Fisher's PLSD for osseous contact effect: Comparison of osseous contact with loaded vs. unloaded times

Groups of comparison by month	Mean difference	Critical difference	P-value
1 Mo. No Load vs. 2 Month No Load	-2.740	6.766	0.9368
1 Mo. No Load vs. 1+ 3 Mo. Load	-13.120	5.184	<0.0001
1 Mo. No Load vs. 2 + 3 Mo Load	-10.210	5.184	0.0001
2 Mo. No Load vs. 1 + 3 Mo Load	-12.840	5.324	<0.0001
2 Mo. No Load vs. 2+3 Mo Load	-9.940	5.324	0.0003
1+3 Mo Load vs. 2+3 Mo Load	2.903	3.074	0.0642

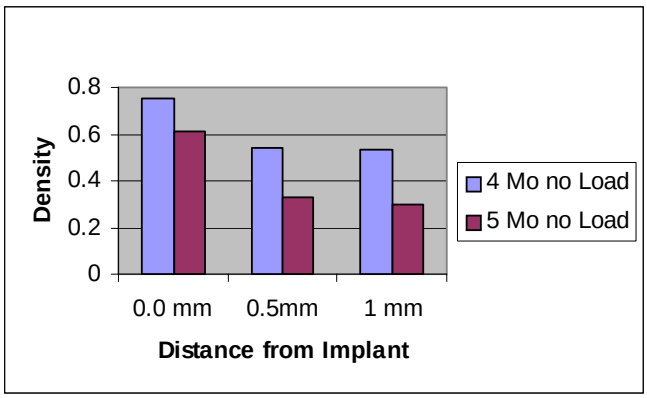

Figure 6. Comparison of bone densities at 4 months and 5 months of no loading.

When comparing the 4-month no load and the 5-month no load implant groups, there was a trend for the bone densities to decrease in the 5 month no load group as compared to the 4 month no load group (Figure 6). There was a statistical significance with a p-value of <0.0001 (Table 5).

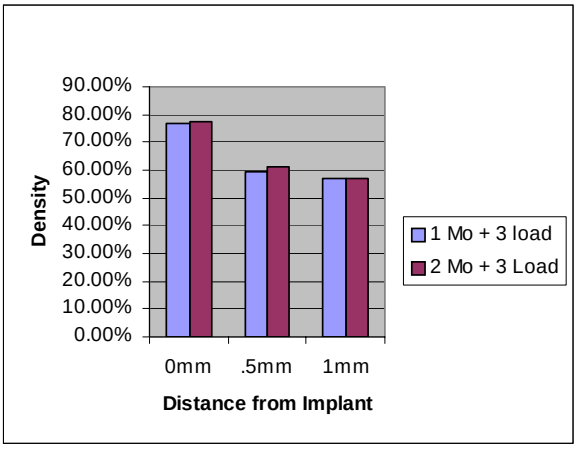

Figure 7. Bar graph comparing the bone densities for the two test groups of 1 month healing plus 3 months of load vs. 2 month healing plus 3 months of occlusal load.

When comparing the two test groups, the 2-month healing plus 3 months of occlusal loading group had slightly higher percentages of mean bone densities than the 1-month healing plus 3 months loading group (Figure 7). This was not statistically significant (p-value = 0.0642) (Table 4).

Table 5. Fisher's PLSD for Osseous Contact Effect: Comparison of Unloaded times for Osseous Contact

Groups of no load time being compared	Mean difference	Critical difference	P-value
1 mo vs. 2 mo.	-1.260	3.027	0.4118
1 mo. vs. 4 mo.	-0.088	5.254	0.9737
1 mo. vs. 5 mo.	19.760	5.254	< 0.0001
2 mo. vs. 4 mo.	1.178	5.259	0.6603
2 mo. vs. 5 mo.	21.028	5.259	< 0.0001
4 mo. vs. 5 mo.	19.850	6.790	< 0.0001

CHAPTER 4
DISCUSSION AND CONCLUSION

Discussion

The percentages of bone density were histomorphometrically measured lateral to the perimeter of the implant at distances of 0.5mm and 1.0mm from the bone-implant interface at various loading sequences. The data from this study was compared to the original data from Vernino et al.[10] that measured the bone densities at 0.0mm, or along the implant perimeter with the same temporal loading sequences as with this study.[10]

There was a difference observed between the bone densities at distances lateral to the implant interface with respect to the various loading sequences in this study. This implies that there is a peri-implant bone reaction that occurs lateral to the implant interface when an implant is placed in function. The occlusal loading and the time that the implant is loaded seem to effect the peri-implant bone by increasing in density. This can be explained by the phenomena of "functional adaptation" or Wolff's Law. This finding is significant in the fact that no other study has verified that Wolff's Law has occurred with dental implants placed into occlusal function.

The 1, 2, and 4 month unloaded implant groups had significantly higher percentages of osseous tissue at lateral distances compared to the 5 month unloaded group. The decreased amount of bone density found at the 5 month unloaded implant group may suggest that there is a critical time period when dental implants should be placed into occlusal function. In this study, it is suggested there is a crucial time period

after 4 months that negative changes in peri-implant bone will occur unless there is loading of the osseous support around the dental implant. Therefore, a dental implant that remains dormant for too long may be at risk for a decrease in bone density. This could be due to a disuse atrophy as a result of no functional stimulation. It has been shown that bone loss will occur when there is decrease of stress placed on the bone.[41] The bone loss can begin as little as a few months and will continue to effect the cortical and trabecular bone long-term.[42]

It has been reported that early occlusal loading may be damaging to the peri-implant bone and will lead to fibrous connective tissue interposition at the implant-interface and eventual implant failure. However, in this investigation there was a 100% success rate of early loaded dental implants in poor quality bone as reported by Vernino et al.[10] It can be assumed that early occlusal loading is in fact beneficial to the patient by decreasing treatment time and preserving alveolar bone.

Bone density is usually higher at the implant interface with a functionally loaded implant. In this study that finding was confirmed. Also found was bone density decreased as the distance increased from the implant interface without accounting for time or loading. However, when loading was considered, the bone density increased laterally but still remained lower than the implant profile (0.0mm) densities. These findings were significant statistically and these results conclude that the greatest amount of bone will be present at the implant-interface. Therefore it is important to consider the bone density of the supporting structures and the implant surface when treatment planning dental implants.

The results of this study can be compared to Gotfredsen et al.[37] The bone reactions adjacent to titanium implants subjected to lateral static load were measured at 0.0, 1.0,

and 2.0mm. The results indicated that laterally loaded test implants exhibited a higher bone density and BIC in comparison to the control implants without lateral load. The mean BIC at the interface was 59% at the control implants and 66%, 66%, and 67% and the test sites. This is in agreement with the current investigation that loaded implants increase in bone density laterally, compared to unloaded controls. Also, the bone density decreased as the lateral distance from the implant interface increased when load was not accounted for. Since Gotfredsen et al. used lateral forces to stimulate a peri-implant bone reaction, this study cannot be fully correlated to the present investigation, which utilized actual occlusal loading, mimicking the clinical setting.

The results of Gotfredesens et al.[37] lateral loading implant study are also in accordance with the observations made in orthodontic studies on the use of dental implants as anchorage in orthodontic therapy. Roberts et al. placed implants in the femur of 14 rabbits and connected the implants with orthodontic coil springs calibrated to deliver a continuous force of approximately 1 Newton (N). There was an increased amount of mineralized bone between test implants and the controls.[43] Wherbein and Diedrich placed 12 implants in the mandible of and the maxilla of 2 foxhounds. The implants were connected to a natural tooth with an orthodontic appliance with 2 N force in 26 weeks. There was more remodeling of the bone and subperiostal bone apposition around test implants compared to the unloaded controls.[44]

Although the findings in this investigation are derived from primate histological samples, there are some similarities and conclusions that can be drawn. This study was conducted in female baboons thathave poor quality of bone usually described by Lekholm and Zarb[1] as type 3 or 4 However, their poor bone quality did not have any effect on the success of the dental implants. Baboons maintain a herbivore diet so their

"functional loading" of dental implants can be questioned. It can be assumed that the animal model presented in this investigation can relate to realistic human clinical applications.

Conclusion

The percentages of bone densities were measured lateral to the perimeter of the implant at distances of 0.5 and 1.0mm with various loading sequences and were compared to the bone-to-implant contact percentages at 0.0mm. The unloaded controls had mean bone densities of 62.5% at 0.0mm, 45.2% at 0.5mm, and 44.1% at 1.0mm. The loaded test group of 1-month healing plus 3 months of occlusal loading exhibited mean bone densities of 76.6% at 0.0mm, 59.2% at 0.5mm, and 55.5% at 1.0mm. The loaded test group of 2 months of healing plus 3 months of occlusal loading expressed mean bone densities of 77.2% at 0.0mm, 61.0% at 0.5mm, and 57.1% at 1.0mm.

The increasing bone densities in the test groups correlate to appositional bone response in the peri-implant and bone-implant areas. The results showed that there was a greater percent of bone density lateral to the dental implants placed into early occlusal function versus the unloaded implants. This can be interpreted as "functional adaptation" or Wolff's Law.

There also appears to be a critical time period of when dental implants should be placed into occlusal function. There may be a resultant decrease in bone density if the dental implant is not occlusally loaded at within that crucial time interval. Thus necessitating the need for a cooridinated treatment plan between the restorative dentist and the surgeon.

Further investigation is needed to determine the direct effect on peri-implant bone that occurs when implants are placed into early occlusal function. There may be more

information gathered by comparing implant surface topographies with early occlusal loading at lateral distances as well. Comparing the Osseotite and CpTi surfaces with the distances and load sequences may provide additional information in regard to the peri-implant bone reaction. The surface topography data was collected in this investigation but was not in the scope of this research project.

REFERENCES

1. Lekholm U and Zarb GA. (1985) Patient selection. In: Branemark PI, Zarb GA & Albrektsson T, eds. *Tissue Integrated Prosthesis. Osseointegration in Clinical Dentistry.* Chicago: Quintessence, pp. 199-209.

2. Engquist B, et al. A retrospective multicenter evaluation of osseointegrated implants supporting overdentures. *Int J Oral Maxillofac Implants* 1988 Summer; 3(2): 129-34.

3. Misch CE. Progressive loading of bone with implant prostheses. *J Dent Symp* 1993 Aug; 1: 50-3.

4. Friberg B. (1994a) *Bone Quality Evaluation during Implant Placement* Odont. Lic. Thesis. Goteberg: Faculty of Odontology, University of Goteberg.

5. Friberg B. (1994b). Treatment with dental implants in patients with severe osteoporosis: A case report. *International Journal of Periodontal Research in Dentistry* 14: 349-353.

6. Trisi P, Rao W. Bone classification: Clinical histomorphometric comparison. *Clin Oral Implant Res* 1999; 10: 1-7.

7. Trisi P, Lazarra R, Rao W, Rebaudi A. Bone-implant contact and bone quality: Evaluation of expected and actual bone contact on machined and Osseotite implant surfaces. *Int J Periodontics Restorative Dent* 2002; 22: 534-45.

8. Gotfredsen K, Nimb L, Hjorting-Hansen E, Jensen JS, Zholmen A. Histomorphometric and removal torque analysis for TiO_2-blasted titanium implants. An experimental study in dogs. *Clin Oral Implants Res* 1992; 3: 77-84.

9. Buser D, Schenk RK, Steinman S, Fiorellini JP, Fox CH, Stich H. Influence of surface characteristics on bone integration of titanium implants. A histomorphometric study in miniature pigs. *J Biomed Mater Res* 1991; 25: 880-902.

10. Vernino A, Kohles S, Holt R, Lee H, Caudill R, Kenealy J. Dual-etched implants loaded after 1-and 2-month healing periods: A histologic comparison in baboons. *Int J Periodontics Restorative Dent* 2002; 22: 3-10.

11. Johansson CB, Albrektsson T. A removal torque and histomorphometric study of commercial pure nobium and titanium implants in rabbit bone. *Clin Oral Implants Res* 1991; 2: 24-29.

12. Ericsson I, Johansson CB, Bystedt H, Norton MR. A histomorphometric evaluation of bone-implant contact on machined-prepared and roughened titanium implants. *Clin Oral Implants Res* 1994; 55: 202-206.

13. Brunski JB, Moccia AF, Pollock SR, Korostoff E, Trachtenberg DI. The influence of functional use of endosseous dental implants on the tissue implants on the tissue implant interface: *I. Histological Aspects* J Dent Res 1979; 58: 1953-1969.

14. Lum LB, Beirne OR, Curtis DA. Histological evaluation of hydroxylapatite-coated versus uncoated titanium blade implants in delayed and immediately loaded applications. *Int J Oral Maxillofac Implants* 1991; 6: 456-462.

15. Akagawa Y, Hashimoto M, Kondo N, Satomi K, Takata T, Tsura H. Initial bone implant interfaces of submergible and supramergible endosseous single crystal sapphire implants. *J Prosthet Dent* 1986; 55: 96-100.

16. Johansson C, Albrektsson T. Integration of screw implants in the rabbit. A 1-year follow-up of removal torque of titanium implants. *Int J Oral Maxillofac Implants* 1987; 2: 69-75.

17. Albrektsson T, Sennerby L. Direct bone anchorage of oral implants: Clinical and experimental considerations of the concept of osseointegration. *Int J Prosthodont* 1990; 3: 30-41.

18. Deporter DA, Watson PA, Pilliar RM, Howley TP, Winslow J. A histological evaluation of a functional endosseous, porous-surfaced, titanium alloy dental implant system in the dog. *J Dent Res* 1988; 67: 1190-1195.

19. Piatelli A, Ruggeri A, Franchi M, Romasco N, Trisi P. A histologic and histomorphometric study of bone reactions to unloaded and loaded non-submerged single implants in monkeys. A pilot study. *J Oral Implantol* 1993; 19: 314-320.

20. Sagara M, Akagawa Y, Nikai H, Tsuru, H. The effects of early occlusal loading on one-stage titanium alloy implants in beagle dogs. A pilot study. *J Prosthet Dent* 1993; 69: 281-288.

21. Akagawa Y, Ichikawa Y, Nikai H, Tsuru H. Interface histology of unloaded and early loaded partially stabilized zirconia endosseous implants in initial bone healing. *J Prosthet Dent* 1993; 69: 599-604.

22. Lazarra RJ, Porter SS, Testori T, Galante U, Zetterqvist L. A prospective multicenter study evaluating loading of Osseotite implants two moths after placement: One-year results. *J Esthet Dent* 1998; 10: 280-289.

23. Balshi TJ, Wolfinger GJ. Immediate loading of Branemark implants in edentulous mandibles: A preliminary report. *Implatn Dent* 1997; 6: 83-88.

24. Tarnow DP, Emtiaz S, Classi A. Immediate loading of threaded implants at stage 1 surgery in edentulous arches: Ten consecutive case reports with 1- to 5-year data. *Int J Oral Maxillofac Implants* 1997; 12: 319-324.

25. Schnitman PA, Wohrle PS, Rubenstein JE, Da Silva JD, Wang N-H. Ten-year results for Branemark implants immediately loaded with fixed prostheses at implant placement. *Int J Oral Maxillofac Implants* 1997; 12: 495-503.

26. Piatelli A, Corigliano M, Scarano A, Quaranta M. Bone reactions to early occlusal loading of two-stage titanium plasma-sprayed implants: A pilot study in monkeys. *Int J Periodontics Restorative Dent* 1997; 17: 163-169.

27. Piatelli A, Paolantonio M, Corigliano M, Scarano A. Immediate loading of titanium plasma-sprayed screw-shaped implants in man: A clinical and histological report of two cases. *J Periodontol* 1997; 68: 591-597.

28. Wohrle PS. Single-tooth replacement in the aesthetic zone with immediate provisionalization: Fourteen consecutive case reports. *Pract Periodontics Aesthet Dent* 1998, 10: 1107-1114.

29. Isidor F. Histological evaluation of peri-implant bone at implants subjected to occlusal overload or plaque accumulation. *Clinical Oral Implants Research* 1997; 8: 1-9.

30. Asidainen P, Klemmetti E, Vuillemin T, Sutter F, Rainio V, Kotilainen R. Titanium implants and lateral forces. An experimental study with sheep. *Clinical Oral Implants Research* 1997; 8: 465-468.

31. Wehrbein H, Glatzmaier J, Yildirim M. Orthodontic anchorage capacity of short titanium screw implants in the maxilla. An experimental study in the dog. *Clinical Oral Implants Research* 1997, 8: 131-141.

32. Akin-Nergiz N, Nergiz I, Schulz A, Arpak N, Niedermeier W. Reactions of peri-implant tissues to continuous loading of osseointegrated implants. *American Journal of Orthodontics and Dentofacial Orthopedics* 1998; 114(3): 292-298.

33. Hurzler MB, Quinones CR, Kohal RJ, Rohde, M, Strub JR, Teuscher U, Caffesse RG. Changes in peri-implant tissues subjected to orthodontic forces and ligature breakdown in monkeys. *Journal of Periodontology* 1998; 69(3): 396-404.

34. Barbier L, Schepers E. Adaptive bone remodeling around oral implants under axial and non-axial loading conditions in the dog mandible. *International Journal of Oral and Maxillofacial Implants* 1997; 12: 215-223.

35. Carr AB, Gerard DA, Larson PE. The response of bone in primates around unloaded dental implants supporting prostheses with different levels of fit. *Journal of Prosthetic Dentistry* 1996; 76: 500-509.

36. Michaels GC, Carr AB, Larsen PE. Effect of prosthetic superstructure accuracy on the osteointegrated implant bone interface. *Oral Surgery, Oral Medicine, Oral Pathology, Oral Radiology, and Endodontics* 1997; 93(2): 198-205.

37. Gotfredsen K, Berglundh T, Lindhe J. Bone reactions adjacent to titanium implants subjected to static load. A study in the dog. (I). *Clinical Oral Implants Research* 2001; 12: 1-8.

38. Frost HM. Wolff's law and bone's structural adaptions to mechanical usage: An overview for clinicians. *Angle Orthodontist* 1994; 64: 175-188.

39. Wolff JD. *The Laws of Bone Remodeling* (translated by Maquet P, Furlong R). Berlin: Springer, 1986.

40. Donath K. *Preparation of Histologic Sections.* Norderstedt, Germany: Exakt-Kuzer, 1998.

41. Allison N, Brooks B. An experimental study of the changes in bone which result from non-use. *Surg Gynecol Obstet* 1921; 33: 250.

42. Kazarian LE, Von Gierke HE. Bone loss as a result of immobilization and chelation. Preliminary results in Maccacca Mulatta. Clin Orthop Rel Res 1969; 65: 67.

43. Roberts WE. Rigid endosseous anchorage and tricalcium phosphate (TCP)-coated implants. *CDA J* 1984 Dec;12(12):158-61.

44. Wehrbein H, Diedrich P. Endosseous titanium implants during and after orthodontic load—an experimental study in the dog. *Clin Oral Implants Res* 1993 Jun; 4(2): 76-82.

BIOGRAPHICAL SKETCH

Lara LeAnn Tull was born and raised in Raymore, Missouri. She attended the University of Missouri-Kansas City for her undergraduate training, majoring in biology. She was then admitted into the University of Missouri-Kansas City School of Dentistry for her dental education and graduated in May 1999, obtaining a Doctorate of Dental Surgery. Following dental school graduation, Dr. Tull continued her dental education at the University of Florida. She obtained a fellowship certificate in the prosthodontic residency in May 2001. She is scheduled to complete a degree of Master of Science with a certificate in periodontics in December 2003.