A MULTIPLE LUCAYAN BURIAL FROM NEW PROVIDENCE, BAHAMAS

John Winter

In 1492, Christopher Columbus described the inhabitants of the Bahamas as being "fairly tall, good looking, and well made" (Morison 1942). Yet some of the Lucayans had "marks of wounds" on their bodies, which they apparently received defending themselves against people from other near-by islands. With the recent interest in Bahamian prehistory (Hoffman 1965; Keegan 1985; Sears and Sullivan 1978; Winter et al. 1985), we are learning more about the cultural adaptation of the Lucayans to their environment and less about the biological development. With so many sites being recorded, where are all the skeletal remains of the Lucayans?

In 1982, William Keegan summarized all the known Lucayan burials since Brooks' study in 1888. He reported on 33 individuals from 11 different sites. All the skeletal remains were associated with an apparent cave interment, and this could account for the small sample sizes for the Bahamas. It appears that during the historic period, the caves were exploited for the bat guano that accumulated within (Craton 1986). The guano was harvested and sold as fertilizer. The author spoke with several older Bahamians, who remember having gone into caves to collect guano in their youth. When they came across objects such as bone or pieces of shell or wood, they would toss aside these objects or carry them out with the guano. Therefore, if the Lucayans practiced only cave burials, then many Lucayans have been utilized by plants as nutrients. Given this possibility, it is clear that the study of any Lucayan remains recovered, no matter how fragmentary, will add to our understanding of Bahamian prehistory.

In August, 1982, the author was shown a 26 foot deep cave from which three human crania had been found and removed. Initially these crania were turned over to the Bahamian police, who realized that they were not modern and therefore they had no jurisdiction over them. It is at this point that the crania appear to have vanished. However, at the bottom of this cave, which measured 13 feet across by 6 feet wide, other human and faunal remains were scattered on the surface. Because of the cramped working conditions, the soil was removed and placed in buckets. The soil was then screened through a ¼ inch wire mesh, to obtain bone fragments that could not be removed upon observation. The excavations revealed that the human and faunal remains had been disturbed in the past as no bones were articulated. The human and faunal remains were recovered from 11 inches of a brown soil, which lay above a compact red clay. This red clay was not penetrated by the bones and appeared to be a sterile zone, at least for the first 2 inches.

During the excavation, it became apparent that more than three individuals were interred. Therefore, all complete and fragmented bones were

analyzed, with proximal, distal, and shaft fragments being isolated and then compared with complete bones to obtain a minimum number of possible individuals. An initial analysis of the paired and single bones indicate that at least 8 adults and 1 child were present in the cave. When considering the context in which the remains were found, it is difficult to determine whether the deceased were placed in the cave one at a time in an upright or sideways fetal position, laid atop one another as a mass burial, or deposited as a secondary burial.

The faunal remains were found to be the vertebrae and ribs of a boa (*Epicrates striatus*), a humerus of a frog, most likely the Cuban tree frog (*Osteopilus septentrionalis*), and a proximal end of a rodent ulna (probably *Geocapromys ingrahami*). As these appear to be isolated individuals, it would seem that they fell into the cave rather than being placed there.

METHODS

In the determination of an individual's sex, various criteria are assessed. The innominates are the most reliable bones for the determination of sex, with a consistency of about 95% (Genovés 1959). The reason for this is the childbearing abilities of the female. The female innominate is broader, the angle of the sciatic notch is wider (about 60 degrees), there is a pre-auricular sulcus, the pubis is longer, and the sub-pubic angle wider. The skull can also be a good indicator of sex with a consistency of about 90% (Krogman 1962). The male cranium is generally larger and heavier than the female cranium, with more pronounced areas for muscle attachment; likewise the mandible is also more robust with a well developed gonial region. The long bones of the male are longer, heavier, and have larger attachment areas for muscles than do their female counterparts. A consistency of about 80% marks this test (Krogman 1962). These are all visual tests.

Several calculated tests can also be employed on the bones. Here measurements are taken on a bone and directly used or placed into a mathematical formula. It is important to note that because of the random variation inherent in such measurements, some bone will be misclassified with a positive probability. This is due to the fact that not all individuals are exactly alike and that some males may be smaller and some females larger than the norm. Therefore, a cut-off point for males/females should be calculated as the skeletal biology of each group differs somewhat.

The use of mid-shaft circumference can produce an 85% measure of accuracy (Black 1978). The use of discriminate function analysis can produce varied measurements of accuracy: 83% using the talus (Steele 1976), 79% using the calcaneus (Steele 1976), 75% using the base of the cranium (Holland 1986), and 83% using the mandible (Giles 1964).

The age of an immature or sub-adult individual is more accurate than an adult as the dental patterns and centers of epiphyseal union are more easily observed in the former. The age of an adult can be estimated by using the pubic symphysis of the innominate and observing any degenerative changes in the bone in that region (Brothwell 1981).

Additional data that can be gathered from individuals are concerned with the modification of the teeth and bones. This modification can be the result of pathological conditions or cultural practices. The dental area is examined for periodontal disease by noting the amount of alveolar resorption, for calcium and food deposits (calculus) on the cervical margins of the teeth, for the decay of the teeth (caries), and for the attrition of the occlusal surface of the molars.

Dental attrition has been related to the masticatory behavior, methods of food preparation, and diet of individuals. A technique to examine the molar wear patterns of hunters/gatherers and agriculturalists was devised by B. Holly Smith (1984). Part of the technique is based upon the amount of cusp removal on the occlusal surface. A scale of 1 to 8 is applied: 1 = a complete cusp, and 8 = only dentin.

Pathological conditions are the result of disease processes which leave their mark on the bone (Ortner and Putschar 1981). This gives some insight into the health conditions of the individual and the population. Unfortunately, not all diseases leave their marks on the bone, so the knowledge of all components of health is incomplete. A description of the pathology rather than a diagnosis of it will be done, as different diseases can cause similar patterns on the bone and the reverse situation is also possible.

THE SKELETAL MATERIAL

As the bones were disarticulated, no information can be gained about a complete individual. This report will then assess the conditions associated with specific bones. Whether or not any of the bone conditions relate to one another cannot be completely ascertained.

The complete skull of an adult female, about 25 years old, exhibited fronto-occipital cranial deformation. This was reconfirmed with a measured cranial index of 92.8, which indicates hyperbrachycrany or a very broad skull. In addition, the total facial index was 82.8, which indicates a broad face or euryprosopy. Columbus reports these traits as being characteristic of the Lucayan Indians (Morison 1942). The skull also has two wormian bones along the lambdoidal suture and complete closure of the supra-orbital foramen; both of these are non-metric or discontinuous traits. There is a depression in the outer surface of the occipital bone, perhaps a traumatic condition (Fig. 1). Post-mortem loss of all the incisors and canines was observed, as well as alveolar resorption of the second left maxillary premolar and molars, the right maxillary premolars and molars, the second left mandibular premolar and molars, and the second and third right mandibular molars. The first right mandibular molar has a wear pattern of 3.

An adult male frontal bone with frontal flattening has two osteomyelitic lesions inside the cranial vault. There is also complete closure of the supra-orbital foramen. A different adult reveals osteoporosis pitting in a pair of right and left parietals near the coronal/sagittal suture and in the occipital bone.

An almost complete child's mandible reveals the eruption of the first permanent molars, indicating death at around 6 years of age. A left portion of an adult female mandible has a large buccal caries at the neck line of the first molar (Fig. 2). There is slight occlusal attrition, 3 on the Smith scale, on the first and second molar. This individual appears to have lacked a third molar, a non-metric or discontinuous trait. There is a left portion of an adult male mandible with only the first and second molar remaining; the other teeth were lost post-mortem. These molars exhibit a slight calculus deposit at the neck line; however, there is an alveolar abscess below the molar.

An adult left maxillary bone, which has only the second premolar and first molar intact and the other teeth lost post-mortem, has an abscess between the area of the second incisor and canine. The amount of dental wear for these teeth is a 3. A complete pair of adult maxillary bones have alveolar resorption of all the premolars and molars, and an abscess in the palate near the left canine (Fig. 3). The right canine of this individual is worn to the dentin, an 8 on the Smith scale.

A left adult male innominate has osteomyelitic lesions in the posterior surface behind the acetabulum, while an adult female sacrum reveals right to left curvature from the superior to inferior surface with incomplete fusion of the first and second sacral vertebrae (Fig. 4). This latter condition may be the result of a trauma. A single lumbar vertebra, from a middle-aged adult, has osteoarthritic perforations in the inferior and superior articular facets.

A right adult ulna reveals a wear pattern in the trochlea notch area, while a left proximal adult ulna has small striations in the anterior shaft region. A left adult radius reveals an inflammation of the radial tuberosity, perhaps the result of trauma. The distal portion of an adult left humerus has an olecranon perforation, a non-metric or discontinuous trait. An oval-shaped lesion is found in the spinous process of an adult left scapula.

Using Steele's (1976) method for the sex determination of the calcaneus and talus, a left calcaneus produced a value of 38.16, while a right talus yielded a value of 41.80. These values would tend to indicate that the bones belonged to an adult male or males.

Examination of the post-mortem teeth reveal a variety of dental conditions. Dental attrition, for the adult teeth, ranges from 2 to 8 on the Smith scale, with upper incisors averaging 4, lower incisors averaging 4.1, canines averaging 4, upper premolars averaging 4.7, lower premolars averaging 2.6, the upper molars averaging 2.3, and the lower molars averaging 4.7. The lack of extreme occlusal wear could indicate that a non-abrasive or a diversified diet was consumed by these people. There is also an erupting third lower molar with no wear indicating that a young adult was interred in the cave. There is a brownish stain on the crown surfaces of all the adult molars and a right upper incisor. This could be the result of smoking or chewing tobacco, a plant which Columbus described in 1492 (Morison 1942). Dental hypoplasia is observed in a left upper canine and incisor, perhaps from the same individual. Dental hypoplasia

appears to result from faulty structural formation caused by either disease or metabolic disorder. All the upper incisors reveal shovel-shaping, a trait characteristic of Amerindian populations. A left maxillary premolar and a right maxillary incisor exhibit extreme lingual sloping wear, perhaps the result of processing cordage. There are two maxillary molars, each with a single occlusal caries as well as fused roots, perhaps the same individual. This could be the result of a genetic condition or disease. Several teeth would appear to be associated with the previously mentioned child's mandible. There are two upper and lower deciduous canines, an upper and lower deciduous premolar, and an unerupted upper permanent incisor with shovel-shaping. There is slight attrition on the deciduous teeth, a 1 on the Smith scale.

CONCLUSIONS

From this small population of New Providence Lucayans, there is some form of periodontal disease in all the adult mandibles and maxilla. This can be brought about by a variety of factors: unclean mouth, irritation from calculus deposits, or a faulty diet. As there are no significant calculus deposits or caries on the remaining teeth, it could be possible that the alveolar resorption was the result of metabolic problems or diet. There are several cases of abscesses within the mouth region which could indicate a possible internal disease problem. The occurrence of osteomyelitic lesions in the cranial and post-cranial skeleton would point towards a bacterial or viral problem.

Although Columbus describes the Lucayans as apparently 'well made' externally, this New Providence population appears to have had numerous internal problems. However, the skeletons from this burial cave could lend support to Columbus' diary in that they had broad heads and may have used tobacco (Morison 1942). If a more complete picture is to be established regarding the biological conditions of the prehistoric Lucayans, then a larger skeletal population and radiocarbon dating will be necessary.

ACKNOWLEDGMENTS

I would like to thank Don and Kathy Gerace of the CCFL Bahamian Field Station, San Salvador, Bahamas for their assistance in obtaining permission to study the skeletons and for logistical support. I would also thank Pericles and Christina Maillis of New Providence, Bahamas for their assistance in providing the contacts in Nassau, and to Gail Saunders of the Bahamas Government's Archives Division for loaning the material. I would like to thank the members of the Bahamas Archaeological Team, the Bahamas Historical Society, and the Bahamas National Trust for their help in recovering the skeletons. Lastly, I would like to thank Dr. Storrs Olson of the National Museum of Natural History-Smithsonian Institution for his analysis of the faunal remains.

REFERENCES CITED

Black, Thomas
1978 A New Method for Assessing the Sex of Fragmentary Skeletal Remains: Femoral Shaft Circumference. **American Journal of Physical Anthropology** 48:227-231.

Brooks, W.K.
1888 On the Lucayan Islands. **Memoirs of the National Academy of Science** 4(2):215-223.

Brothwell, D.R.
1981 **Digging up Bones**. Ithaca, New York: Cornell University Press.

Craton, Michael
1986 **A History of the Bahamas**. Waterloo, Ontario: San Salvador Press.

Genovés, Santiago C.
1959 **Diferencias Sexuales en el Hueso Coxal**. Mexico, D.F.: Instituto de Historia.

Giles, Eugene
1964 Sex Determination by Discriminant Function Analysis of the Mandible. **American Journal of Physical Anthropology** 22:129-136.

Hoffman, Charles
1967 **Bahama Prehistory: Cultural Adaptation to an Island Environment**. Ph.D. dissertation, University of Arizona. Ann Arbor, Michigan: University Microfilms 68-1018.

Holland, Thomas
1986 Sex Determination of Fragmentary Crania by Analysis of the Cranial Base. **American Journal of Physical Anthropology** 70: 203-208.

Keegan, William F.
1982 Lucayan Cave Burials from the Bahamas. **Journal of New World Archaeology** 5:57-65.

1985 **Dynamic Horticulturalists: Population Expansion in the Prehistoric Bahamas**. Ph.D. dissertation, University of California, Los Angeles. Ann Arbor, Michigan: University Microfilms 85-19111.

Krogman, Wilton
1962 **The Human Skeleton in Forensic Medicine**. Springfield, Illinois: Charles C. Thomas.

Morison, Samuel E.
1942 **Admiral of the Ocean Sea**. Boston: Little, Brown Co.

Ortner, D.J. and W.G.J. Putschar
1981 **Identification of Pathological Conditions in Human Skeletal Remains**. Washington, D.C.: Smithsonian Institution Press.

Sears, William and Shaun Sullivan
1978 Bahamas Prehistory. **American Antiquity** 43:3-25.

Smith, B. Holly
1984 Patterns of Molar Wear in Hunter-Gatherers and Agriculturalists. **American Journal of Physical Anthropology** 63: 39-56.

Steele, D.G.
1976 The Estimation of Sex on the Basis of the Talus and Calcaneus. **American Journal of Physical Anthropology** 45: 581-588.

Winter, John, Julian Granberry and Art Liebold
1985 Archaeological Investigations within the Bahamas. **Proceedings of the Tenth International Congress for the Study of Pre-Columbian Cultures of the Lesser Antilles** (Martinique 1983), pp. 83-92.

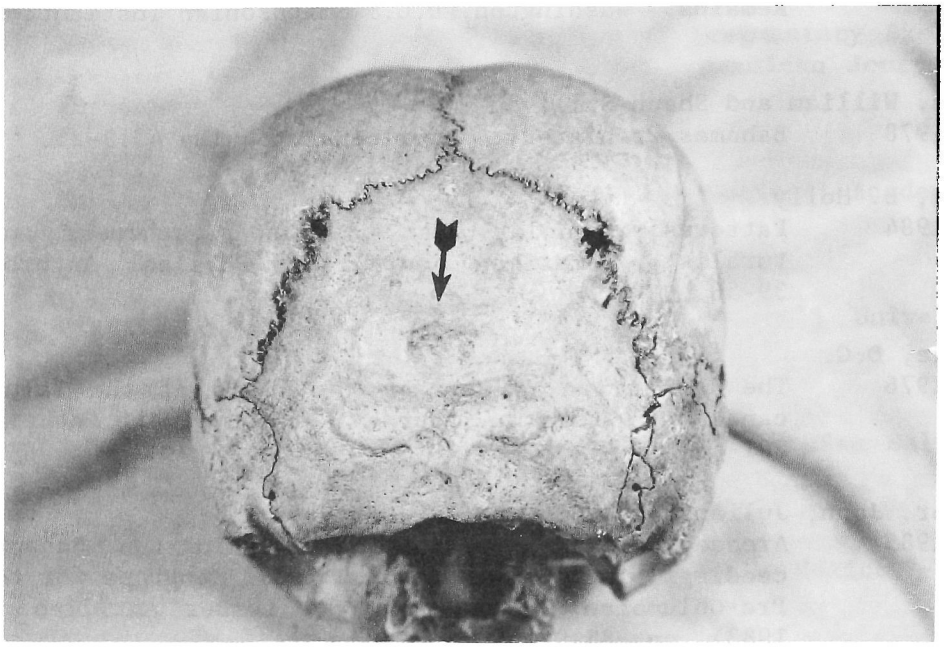

Figure 1. Female skull with depressed occipital region.

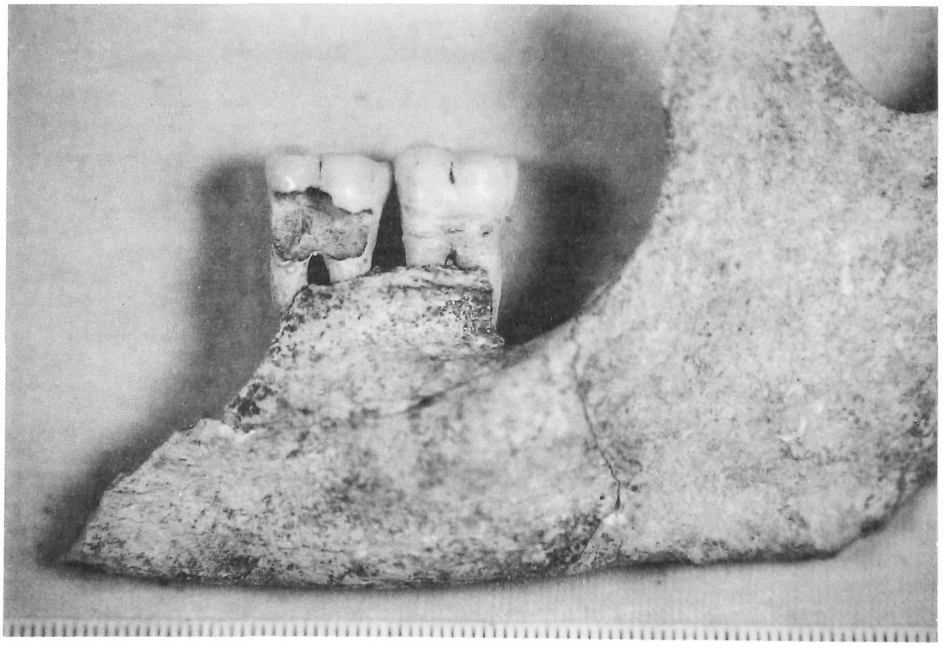

Figure 2. Buccal caries on first mandibular molar.

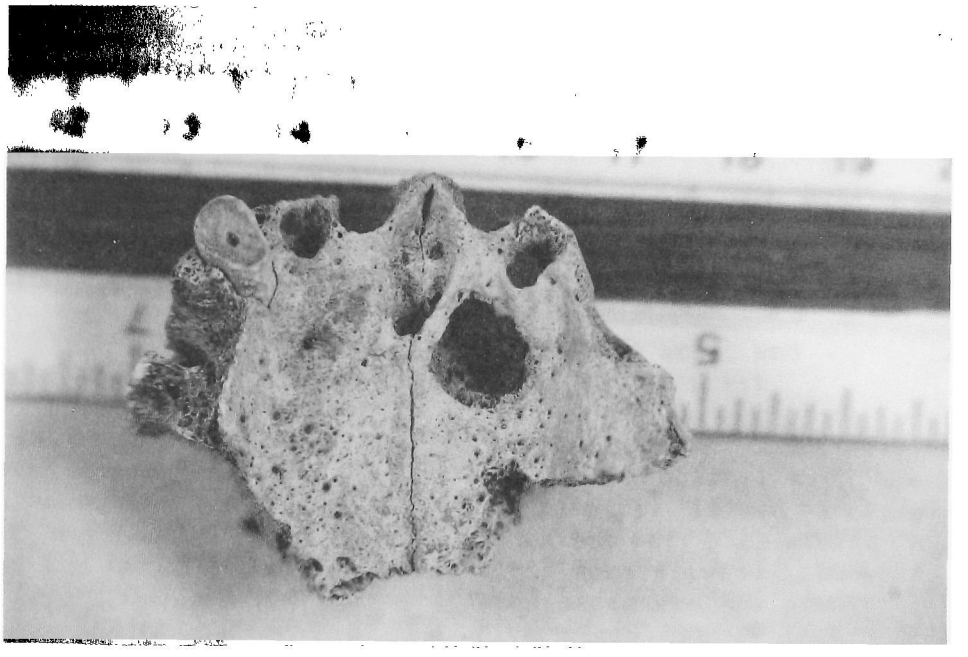

Figure 3. Abscess in maxillary palate.



Figure 4. Curvature of a female sacrum.