AN OSTEOLOGICAL ANALYSIS OF THE HUMAN BURIALS RECOVERED FROM MAISABEL: AN EARLY CERAMIC SITE ON THE NORTH COAST OF PUERTO RICO

Linda C. Budinoff

Maisabel, a Saladoid/Ostionoid site on the north coast of Puerto Rico, yielded 34 human burials during excavations sponsored by the Centro de Investigaciones Indígenas de Puerto Rico. An osteological analysis of these skeletons has been completed (Budinoff 1986), and its results are summarized in the present paper. In addition, demographic inferences are offered, rather than simply presenting burial-by-burial descriptions. Certain pathologies are described in detail because they are important for understanding general health conditions in the prehistoric settlement. Finally, cultural modifications of the bones and stature estimations are discussed.

DEMOGRAPHY

Thirty-four individuals is a small sample of the many burials that must exist at the Maisabel site. Nevertheless, it is probably a fairly representative sample since many age groups are present and the adult sex ratio is 1:1. There are 14 males and 14 females. These 28 adults range from age 20 to old age. There are six children, ranging from one to five years old. The only age groups not represented are older children and adolescents, and as these are groups generally with low mortality rates, one might not expect to find many in a sample of 34.

Since the Maisabel burials date to both Saladoid and Ostionoid occupations, the sample cannot be considered a "mortuary population." However, certain insights and general conclusions may be presented at this time. Furthermore, the conclusions reached here should be considered as hypotheses to be tested using other well documented skeletal samples recovered from Caribbean sites.

(1) Males seem to have lived longer than females. Of the 14 males, nine lived to be about 45 years or older, while of the 14 females, only three survived to this age. More deaths of females occurred during their 20s and 30s, the childbearing years. Elevated female mortality during the adult lifespan is typical of most skeletal populations (Lovejoy et al. 1977). If high levels of warfare had been common, we would expect the opposite pattern: that is, male mortality would have been elevated.

Two of the Maisabel adult males show evidence of violent death, burials 4 and 17. Burial 4 died when he was 45 years or older. For this individual, the evidence is dramatic. Apparently, he was killed by a stingray spine thrust into the chest (Fig. 1). Evidence for the violent death of burial 17 (Fig. 2) is less direct, but still suggestive. This young male, aged about 29 years, almost certainly had his right arm severed. The right

humeral midshaft has two sets of cutmarks (Figs. 3-5): one very deep and made with a bifacial tool, the other set faint and done perhaps with a sharp, smoother-edged tool. Internal striae within the cutmark grooves are evidence of bifacial tool use. The cuts show no sign of healing, thus probably were made immediately prior to death, or soon after. During excavation no right forearm or right hand bones were recovered, which is further evidence that these body parts were severed. Severing of body parts in association with violent death is a pattern archaeologists have noted in many cultures and time periods.

Two violent deaths out of 14 adult males do not necessarily suggest high levels of warfare. One male (burial 4) was well into middle age and crippled with an infectious bone disease when he died. The other male (burial 17) may have been tortured and executed. If warfare was endemic, we would not expect to see so many males surviving into middle age.

(2) Another general demographic conclusion is that few people of either sex survived to old age. Very few individuals exhibit the common, inevitable degenerative changes of old age such as advanced arthritis, osteophytosis, and osteoporosis. Instead, we have evidence for infectious disease in several individuals, possible cases of cancer, and such poor oral health that, in at least one case, dental abscessing may have spread infection and caused death.

PATHOLOGY

Since nearly every adult skeleton exhibited some form of dental pathology, these will be discussed first. In one or two cases I suspect that infections we observed in other parts of the skeletons initially began in the mouth, so it is necessary to appreciate first the severity of some of these dental pathologies.

Severe dental pathologies were the most common health problems among the Maisabel inhabitants, during both the Saladoid and the Ostionoid occupations. Many of the site's adult dentitions are characterized by high caries incidence, severe wear, dental calculus, and frequent antemortem chipping. Severe alveolar abscesses and antemortem tooth loss are common in some of the older people.

Several agents in the diet were responsible for these problems.

(1) **Sand**. Sand probably adhered to foods such as dried fish, shellfish, and land crab. This abrasive causes rapid wear.

(2) **Hard substances**. Land crabs were certainly important in the Saladoid diet and frequently may have been eaten with shell adhering to the flesh. Cracking the crab shells with the teeth, either purposefully or accidently, undoubtedly caused much of the chipping present on the molars. Cracking animal bones with the teeth probably had similar effects. The chipping takes a variety of forms. Sometimes it is just a small piece of the crown that has splintered off, but often a sizeable corner of the molar has deeply sheared off, exposing a large area of dentin. That these chips

were lost during life is evidenced by the smoothing of the edges that occurred later during chewing.

Chipped teeth wear faster than unchipped teeth. Compared to teeth from the well-known Libben site (Ottawa County, Ohio, USA) the Maisabel dentitions wore faster (Lovejoy 1985). For instance, in the Maisabel dentition there is considerably more wear on the first molar by the time the second molar has erupted, compared to the Libben first and second molar wear patterns. Much sand was ingested in the Libben diet, but antemortem chipping is not nearly as frequent as what we see on the Maisabel teeth. I suspect that the chipping is responsible for the faster rate of wear at the Maisabel site.

(3) **Carbohydrates**. Undoubtedly, the Maisabel diet was high in carbohydrates (such as manioc) and this led to plaque formation on the buccal and lingual surfaces of the teeth. When plaque calcifies it is called calculus, and this is what preserves on skeletal remains. Calculus deposits were observed on both adult and child dentitions. Plaque and calculus are irritants, which may lead to periodontal disease and decay at the necks of teeth. Nearly all of the caries in the Maisabel teeth were radicular (at the neck of the tooth); occlusal caries were very rare.

The diagram in Figure 6 illustrates how the effects of the three dietary elements of sand, hard substances, and carbohydrates can aggravate caries formation and cause the eventual loss of teeth. Both heavy wear from abrasives and chipping from the crushing of hard substances frequently result in the exposure of the pulp cavity, thus providing an easy entry point for bacteria. Decay-causing bacteria thrive in plaque. The dental caries and plaque deposits eventually result in alveolar abscesses (both periapical and periodontal) causing erosion of the bone that supports the tooth. The teeth loosen and consequently fall out.

Dental chipping, radicular caries, alveolar abscesses, and frequent antemortem tooth loss are common during both the Saladoid and Ostionoid occupations at Maisabel. This suggests that the kinds of foods utilized and the food preparation techniques responsible for these dental pathologies were continuous from one culture series to the next.

The Maisabel dental chipping pattern is very interesting, and resembles that described by Turner and Cadien (1969) for the Eskimos. They use the term "pressure-chipping" because the fractures resemble flake scars on chipped stone artifacts. Among the Eskimos, Turner and Cadien (1969) find no sex differences in chipping frequency, but that it is age-related. They conclude that the chips primarily are related to the diet (not occupation) and that they are caused by crushing hard substances such as bone. Likewise, among the Maisabel individuals there are no sex differences in chipping frequency; chipping of one or often several teeth is very common in both sexes after about age 25. Further, chipping is absent in Maisabel children, although they do exhibit other dental pathologies such as calculus deposits and heavy wear. Perhaps the children's diets included a relatively high proportion of soft foods, and only in adulthood did foods containing hard substances like invertebrate hard parts and bone become important.

Figure 7 shows a mandible fragment displaying dental calculus, radicular caries, and chipping. These teeth belonged to a woman aged between 35 and 40 years.

The diet of the Maisabel inhabitants created two sets of problems. First, since the people were horticulturalists, the diet was high in carbohydrates and therefore cariogenic, resulting in a high frequency of dental decay. Second, the heavy reliance upon land crabs and shellfish required their teeth to crush hard substances with the same destructive results that Eskimos achieve by chewing bones. It is no wonder that many of the older individuals lost nearly all of their teeth and several individuals display multiple alveolar abscesses.

When dental disease is severe the infection can spread to other parts of the body. A possible example of this is seen in burial 4, an adult male. Periosteal reactive bone is present on nearly all of the longbones including femora, tibiae, fibulae, patellae, arm bones, and the sternal ends of the clavicles (Figs. 8-9). This reveals a disseminated inflammatory condition. Infection has entered the bloodstream and has been carried throughout the body. This condition is known as hematogenous osteomyelitis and was not uncommon in the preantibiotic era (Ortner and Putschar 1985:121-123). It is quite likely that the decay or abscessing seen in the jaws of burial 4 was the initial focus of the infectious organism. Other common sources of infection in adults are skin festerings such as boils, as well as open fractures and wounds. Most hematogenous osteomyelitis patients are infected by the *Staphlococcus aureus* bacterium (Hoeprich 1983:1318). In burial 4 the disease was a chronic, painful condition that persisted for an extensive period of time without causing death. As mentioned above, this man ultimately was killed by a stingray spine pushed into the chest cavity.

Another possible case of hematogenous osteomyelitis is observed in the cranial vault of burial 30 (Fig. 10). Along both branches of the middle meningeal artery are active osteolytic lesions eroding into the diploe. Ear infections spread easily into the meninges, thus implicating this site as the primary focus of infection. Alternatively, these lesions could be evidence of hemangiomas, which are tumors of the bone occurring adjacent to blood vessels. They are common, rarely cause symptoms, and principally are seen in the skull and vertebral bodies (Boyd 1970:1340). A less likely consideration is that the lesions were caused by meningiomas, or tumors of the meninges. Meningiomas, however, tend to appear adjacent to major venous sinuses (Anderson 1985:21, 60), not along the meningeal arteries as exhibited in this specimen.

In burial 5 we have definite evidence for a chronic middle ear infection, with lytic lesions that eventually worked their way through the petrous portion of the temporal bone into the middle cranial fossa. This infectious spread certainly could have been the cause of death. Further, there is an infection in the temporomandibular joint space, with a fistulous perforation of the medial half opening into the epidural cavity of the middle cranial fossa. We do not know why an infection would occur in the temporomandibular joint. Possibly it was a cancer that metastasized there from another part of the body.

Large quantities of bacteria may enter the blood stream from periodontal abscesses because there is great contact with adjacent vascular and lymphatic channels in the jaw. Lymphatic drainage from the gums takes a fairly direct route to the heart (Woodburne 1983:166). If the bacteria settle in the heart or its pericardium, death can result quickly from acute bacterial endocarditis (lesions in the valves), or from pericarditis (distention of the heart's sac, which then seriously interferes with its action) (Boyd 1970:531, 570). Burial 7 displays exceptionally large alveolar abscesses on both sides of the mandible, even along the ascending ramus of the left side (Fig. 11). This dangerous condition could have been the cause of death, by providing an entry point for an infection into the circulatory system.

To summarize the pathologies, very few people in the Maisabel skeletal sample reached old age. Most died before the degenerative diseases of old age became manifest. However, many of the jaws appear as if they belong to 70 or 80 year old individuals; that is nearly edentulous, with the few remaining teeth worn to pegs, and much of the sustaining alveolus resorbed. Yet these jaws belong to people only in middle-age. It is probable that most of these people were dying from both chronic and acute infectious diseases. In some cases I have noted that a disease originated as a dental pathology, thereupon spreading to other regions of the body.

Not only were diseases of old age uncommon, but bone fractures were rare. Only one case was diagnosed--a well-healed ulnar fracture from burial 10. This makes sense, however, because the incidence of fractures is relatively low among sedentary, horticultural groups. Compared to hunter-gatherer societies, horticulturalists tend to be in fewer situations resulting in physical traumas, except of course for systematic warfare.

CULTURAL MODIFICATIONS

Several individuals display upper incisors worn at a steep angle on the labial sides. Unusual occlusion resulting from alveolar prognathism generally was responsible for the steep wear. Alveolar prognathism is a genetically derived characteristic, thus in these cases I would not ascribe cultural practices as a causative factor. However, there is one individual (burial 9), a 30 year old male, whose left maxillary incisors, canine, and first premolar exhibit unusually steep wear (Fig. 12). This seems to have been caused by pulling a material downward and out through the left side of the mouth. The steep wear is not present on the right maxillary teeth. This individual also is unusual because the buccal and lingual surfaces of the teeth are stained by a rusty red color. Further, there are no caries or antemortem chipping on the teeth, which is unusual for a 30 year old individual from this sample. It is difficult to say what caused the red staining. One other person from the sample has the dental stains. This is a 30 year old woman represented by burial 19A. The roots of her teeth are stained more noticeably than the enamel.

Fronto-occipital cranial deformation is apparent on several individuals and from each occupation represented at Maisabel. Three good context Saladoid burials (numbers 2, 4 [Fig. 1] and 17 [Fig. 2]), one Saladoid/Ostionoid transitional burial (number 7), and one good context Ostionoid

burial (number 26) display this type of skull deformation. This variety of deformation is an intentional modification of the head shape, and is not acquired passively by lying on a cradleboard. The most common method is tight wrapping with cloth bands and tying small boards or other flat objects against the frontal and occipital bones (Ubelaker 1978:71).

STATURE

Stature was estimated by fitting the maximum lengths of the longbones into regression equations published by Trotter and Gleser (1958). Except for burial 23, estimates were attempted using only skeletons with entirely intact longbones such as femur, fibula, tibia, humerus, and radius. However, curiosity about the remarkably small longbone shafts of burial 23, an old woman, led me to reconstruct her nearly complete humerus, in order to estimate roughly her height. She was a tiny person, probably about 4 feet 9 inches.

Except for this small old woman, statures for the other individuals are close to average heights of such North American aboriginal groups as Indian Knoll, Pecos Pueblo, Libben, and the Haida (Tague 1986). Maisabel females range from approximately 4 feet 9 inches (144.8 cm; the tiny woman) to 5 feet 2.5 inches (158.8 cm), while the males range from 5 feet 4 inches (162.6 cm) to 5 feet 7.5 inches (171.5 cm).

Burial 16 is a well-preserved four year old child's skeleton (Fig. 13). Several of its maximal diaphyseal lengths were measured and compared with those published for Arikara children (North American Plains Indians) (Ubelaker 1978). The Maisabel children matched the Arikara of the same dental age; hence, again, this Caribbean population seems to fall within the normal height ranges of North American aboriginals.

SUMMARY AND CONCLUSIONS

I will now itemize the major findings of the osteological study.

1. Males lived longer than females. This is the typical pattern of most skeletal populations, given low levels of warfare. Many females were dying during the childbearing years.

2. Few people of either sex lived well into old age. Advanced degenerative changes on the postcrania were observed among only several burials.

3. The diet of the Maisabel site inhabitants throughout the Saladoid and Ostionoid occupations resulted in several dental pathologies. Sand adhering to foods, exoskeleton and shell adhering to invertebrates, and high percentages of carbohydrates all conspired to destroy the teeth. Many middle-aged people had the mouths you would expect on very old people.

4. Infectious disease was common, and sometimes may have been a consequence of (secondary to) dental infection.

5. Interesting continuities between Saladoid and Ostionoid occupations are apparent. Although there were shifts undoubtedly in dietary patterns following the Saladoid occupations (Siegel and Bernstein 1987), the use of certain key food groups must have remained constant. Evidence for this is the seemingly identical patterns of dental pathology in the two cultural series, as represented in the Maisabel skeletal sample.

Another continuity is that fronto-occipital cranial deformation was practiced during the Saladoid, terminal Saladoid, and Ostionoid occupations. It is not present on all skulls during any one time period, yet it is clearly a cultural practice throughout the occupational span of the site. Further, at the Maisabel site the deformed skulls are predominantly male.

Inferences based upon dental pathologies and artificial cranial deformations observed in the Maisabel skeletal sample support the notion that there was an *in situ* cultural development from the Saladoid to the Ostionoid occupations in Puerto Rico. Importantly, this study has provided independent physical anthropological evidence to compare and contrast with linguistic and archaeological evidence (see Rouse [1986:126] for a discussion of this point) synthesized earlier by Rouse (1986).

ACKNOWLEDGMENTS

I wish to thank the Centro de Investigaciones Indígenas de Puerto Rico, Inc. for sponsoring my analysis of the Maisabel skeletal materials, and Rosa García and Peter Siegel for their hospitality during my stay in Puerto Rico. Allen Hirsch photographed the bones in the lab, for which I am grateful. I also thank Drs. Steven Ward and Owen Lovejoy for their diagnoses of several bone pathologies, and Peter Siegel for his comments on this paper.

REFERENCES CITED

Anderson, J.R. (editor)
1985 **Muir's Textbook of Pathology**, Twelfth Edition. Edward Arnold Publishers, Ltd., London.

Boyd, W.
1970 **A Textbook of Pathology: Structure and Function in Disease**, Eighth Edition. Lea and Febiger, Philadelphia.

Budinoff, L.C.
1986 Maisabel skeletal study. Manuscript on file, Centro de Investigaciones Indígenas de Puerto Rico, Inc.

Hoeprich, P.D. (editor)
1983 **Infectious Diseases**. Harper and Row Publishers, Philadelphia.

Lovejoy, C.O.
1985 Dental wear in the Libben population: its functional pattern and role in the determination of adult skeletal age at death. **American Journal of Physical Anthropology** 68:47-56.

Lovejoy, C.O., R.S. Meindl, T.R. Pryzbeck, T.S. Barton, K.G. Heiple, and D. Kotting
1977 Paleodemography of the Libben site, Ottawa County, Ohio. **Science** 198:291-293.

Ortner, D.J., and W.G.J. Putschar
1985 **Identification of Pathological Conditions in Human Skeletal Remains**. Reprint edition of Smithsonian Contributions to Anthropology 28.

Rouse, I.
1986 **Migrations in Prehistory: Inferring Population Movement from Cultural Remains**. Yale University Press, New Haven.

Siegel, P.E., and D.J. Bernstein
1987 Site structure, settlement organization, and sampling: a case study from the north coast of Puerto Rico. Paper presented at the 52nd Annual Meeting of the Society for American Archaeology (Toronto).

Tague, R.G.
1986 **Obstetric Adaptations of the Human Bony Pelvis**. Unpublished Ph.D. dissertation, Department of Biology, Kent State University.

Trotter, M., and G.C. Gleser
1958 A pre-evaluation of estimation of stature based on measurements of stature taken during life and of long bones after death. **American Journal of Physical Anthropology** 16:79-123.

Turner, C.G., II, and J.D. Cadien
1969 Dental chipping in Aleuts, Eskimos and Indians. **American Journal of Physical Anthropology** 31:303-310.

Ubelaker, D.H.
1978 **Human Skeletal Remains: Excavation, Analysis, Interpretation**. Aldine Publishing Company, Chicago.

Woodburne, R.T.
1983 **Essentials of Human Anatomy**, Seventh Edition. Oxford University Press, New York.

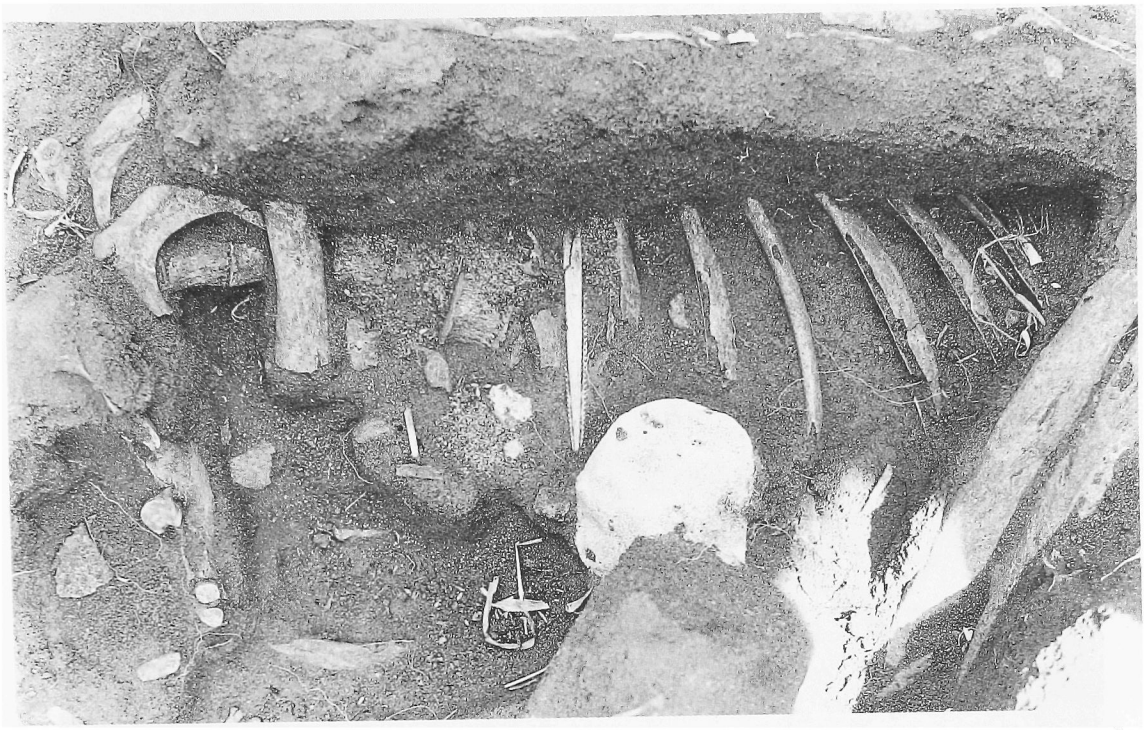

Figure 1. Burial 4 as it was recovered in the field. This individual is in a flexed fetal position. Notice the stingray spine projectile point parallel with the ribs.

Figure 2. Burial 17 as it was recovered in the field. This individual is in a flexed seated position. Most of the bones of this individual were present, except for the lower right arm.

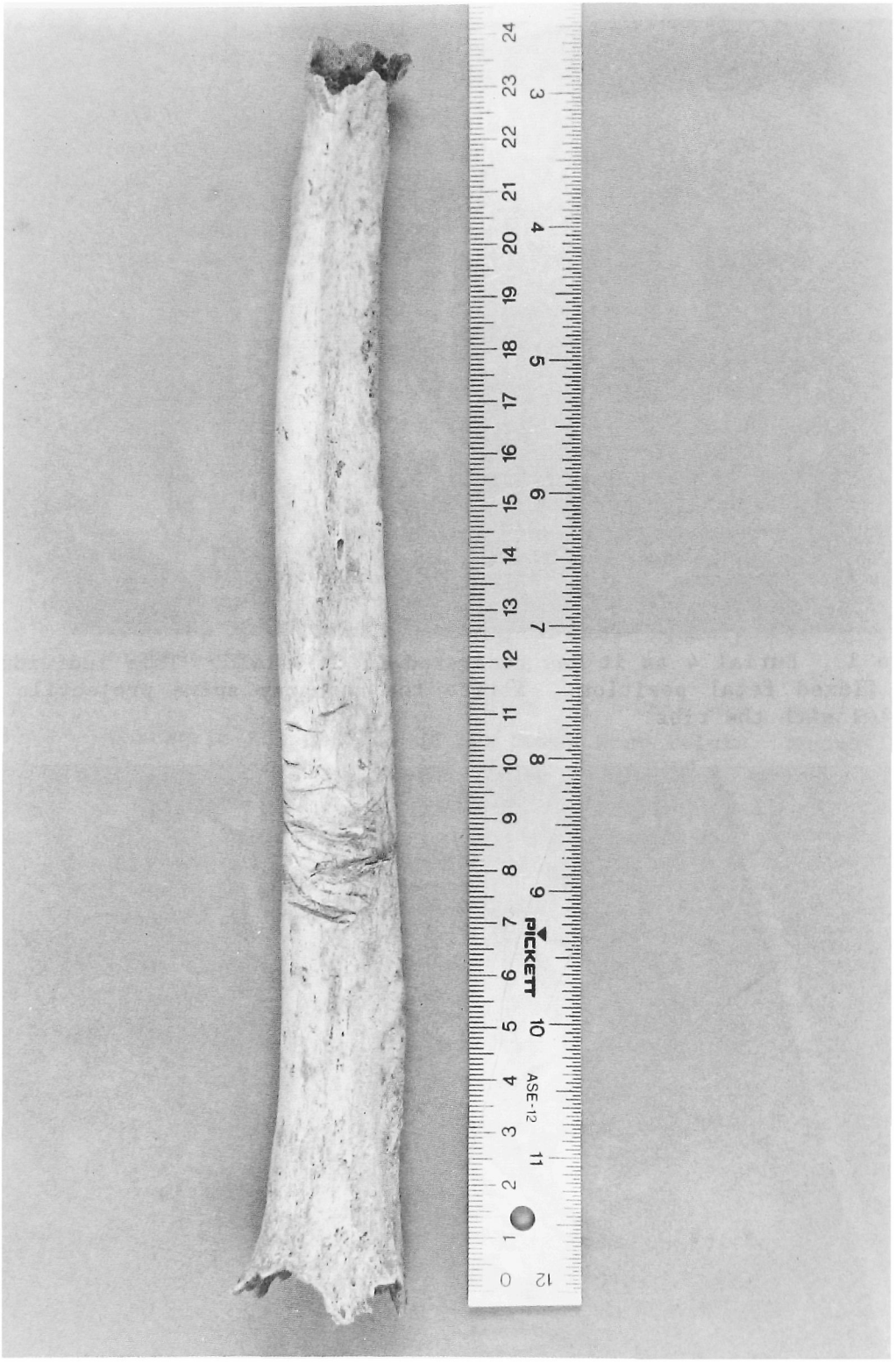

Figure 3. Right humerus of burial 17, displaying one set of parallel cutmarks in the mid to upper shaft region of the bone.

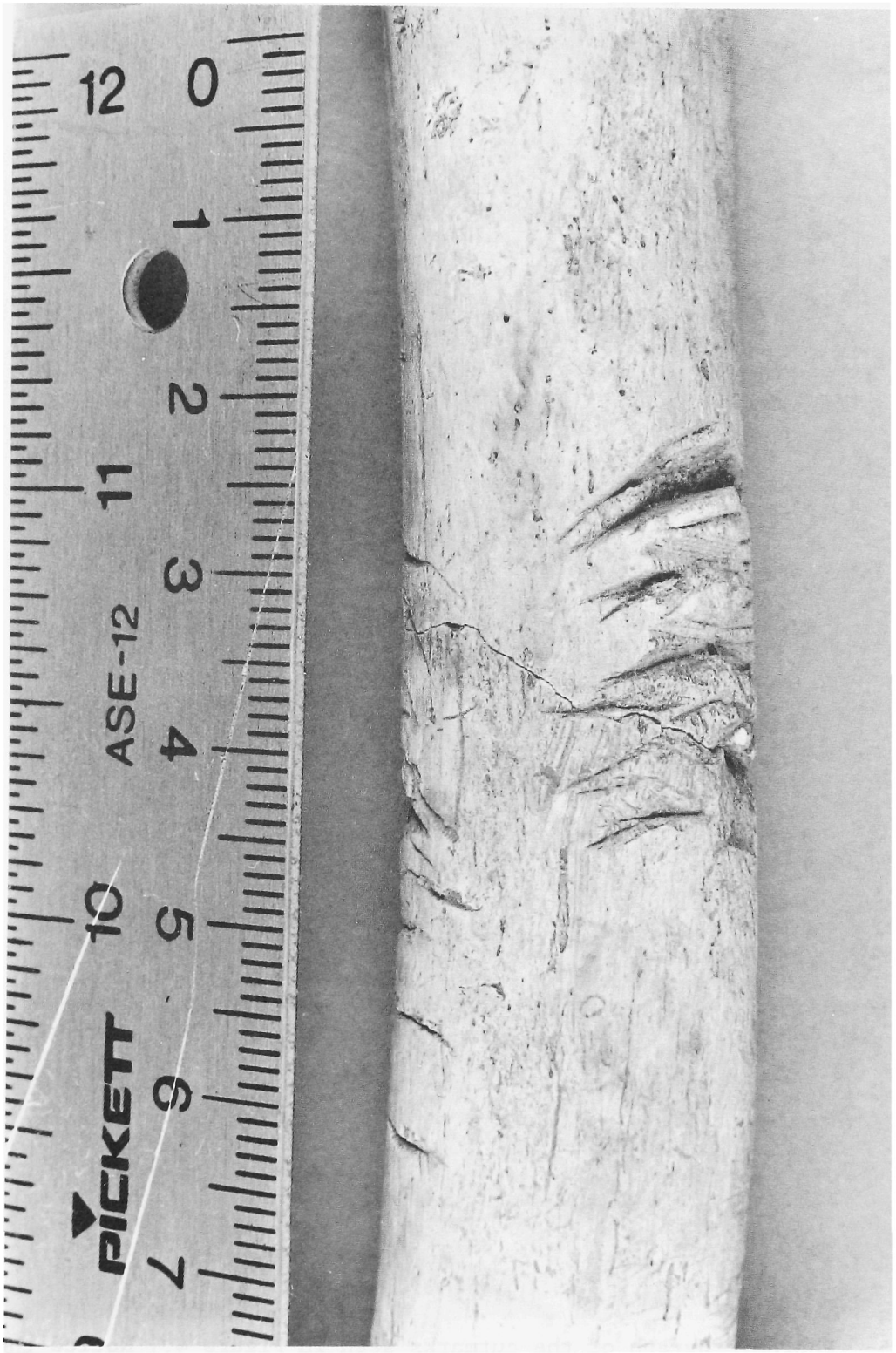

Figure 4. Cutmarks on the lateral side of the mid to upper portion of the right humeral shaft (burial 17). These cutmarks extend from the center of the lateral surface to the posterior aspect of the bone.

Figure 5. Photomicrograph of the cutmarks seen in Figure 4. Notice the V-shaped character of most of these marks, a distinguishing feature between knife marks and rodent gnaw marks. Rodent gnaw marks characteristically are U-shaped. For scale refer to Figure 4.

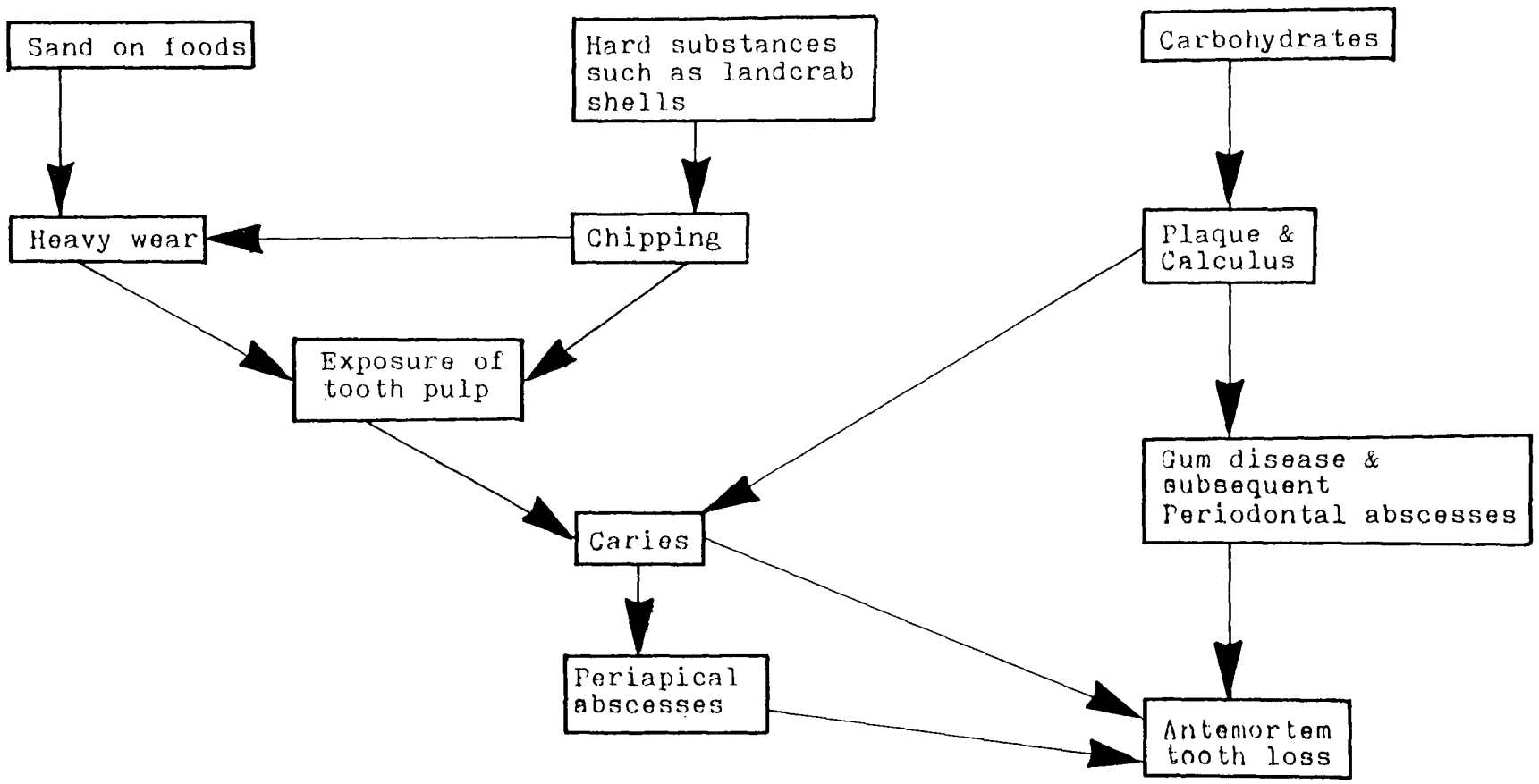

Figure 6. Major destructive agents in the Maisabel diet whose effects combine to cause dental caries, antemortem tooth loss, and other pathologies.

Figure 7. Mandible fragment from burial 25 displaying dental calculus, radicular caries, and chipping.

Figure 8. Longbone fragments from burial 4 exhibiting periosteal reactive bone, revealing a disseminated inflammatory condition.



Figure 9. Periosteal reactive bone from burial 4.

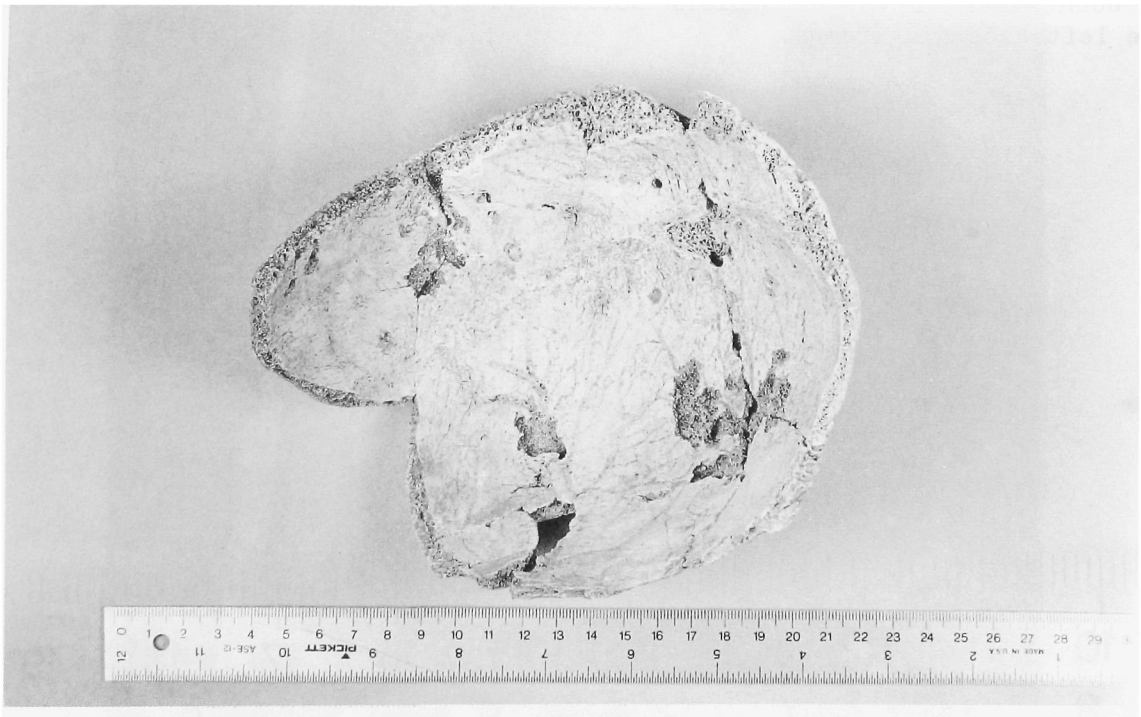

Figure 10. Cranial vault of burial 30. Notice the osteolytic lesions along both branches of the middle meningeal artery. This is a possible case of hematogenous osteomyelitis.

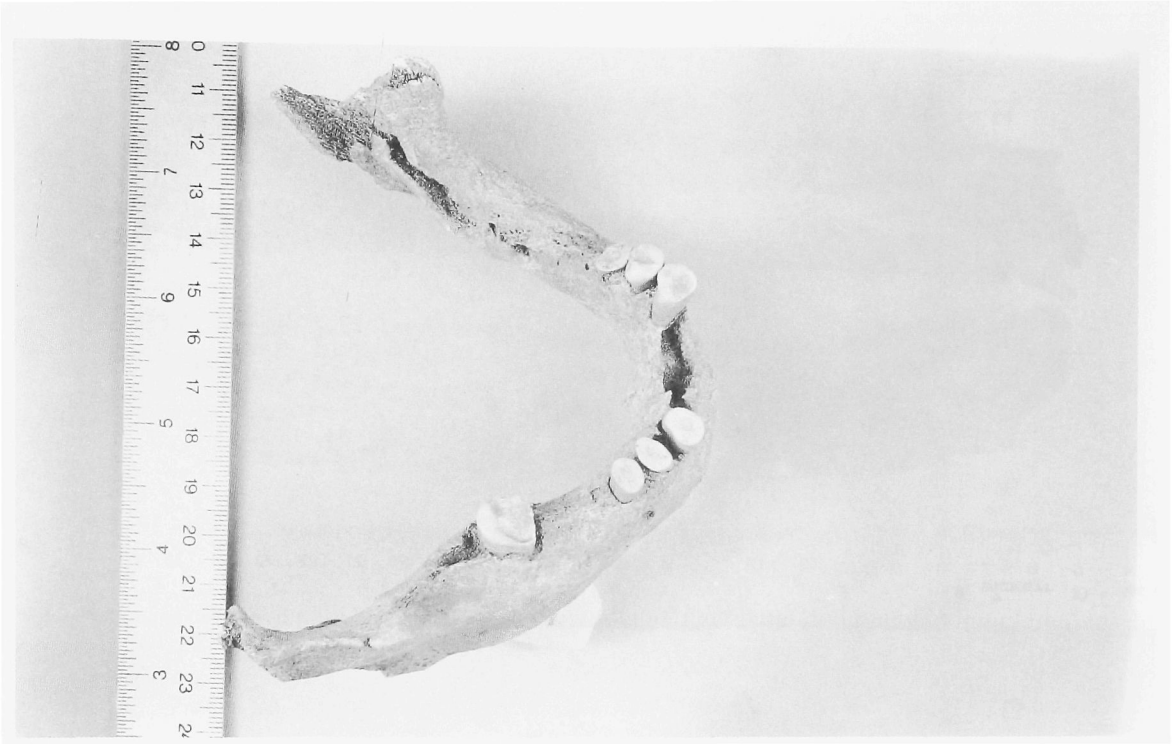

Figure 11. Mandible from burial 7. Large alveolar abscesses are present on both sides of the mandible. Notice, also, the abscess extending along the left ascending ramus.

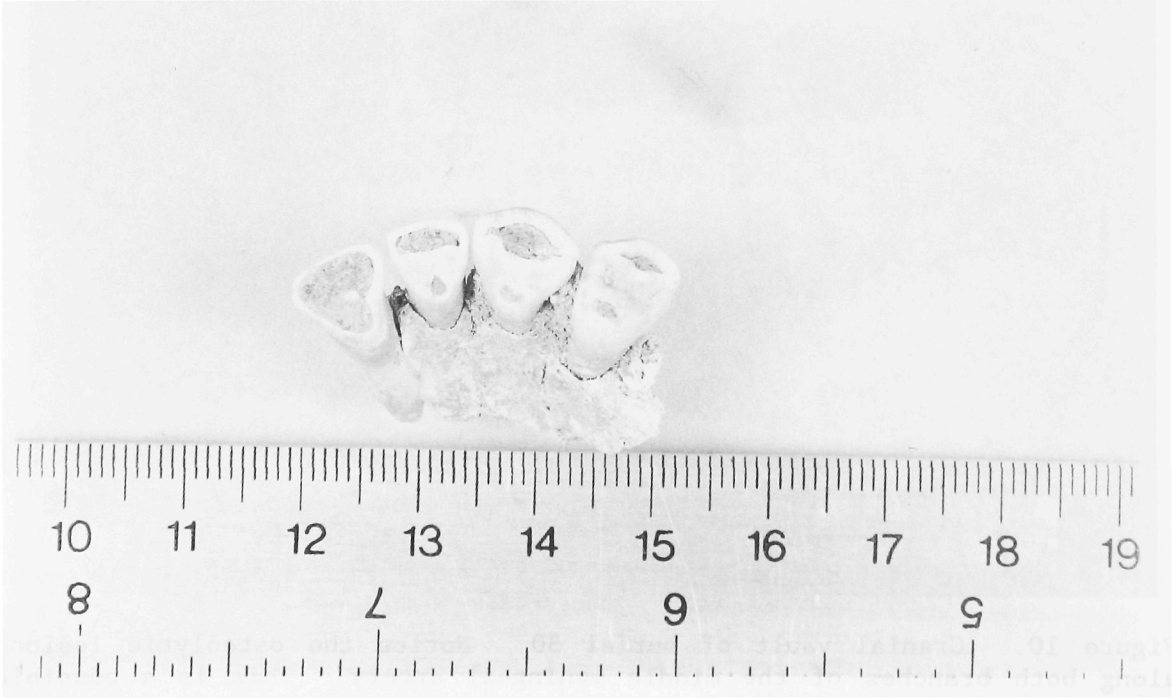

Figure 12. Fragment of left maxilla from burial 9. Notice the steep wear of the incisors, canine, and first premolar.

Figure 13. Burial 16 as recovered in the field. This is a well-preserved four year old child's skeleton.